

OLFACTORY BULB CONTUSION: MRI AND HISTOLOGICAL CORRELATION

M.E. Farrugia, J.I. O'Riordan, Department of Neurology, Ninewells Hospital and Medical School, Dundee

SUMMARY

This case report discusses the correlation between atypical neuroimaging appearances and the histological findings of a somewhat common presentation of brain contusion. A patient presents with headache and a confusional state. Neuroimaging shows atypical-looking mass lesions arising from both olfactory grooves. He undergoes a craniotomy and exploration. At surgery, there is evidence of a frontal skull fracture, which was not evident on any of his previous imaging, and histological examination confirms contusion of the olfactory bulbs.

CASE REPORT

A 52-year-old man, unemployed, returned from a holiday abroad complaining of a frontal headache and of general malaise. He described himself as having become more irritable and short-tempered, and his partner confirmed that he had become somewhat disinhibited. He complained of abdominal pain, associated with nausea and vomiting. This was attributed to an alcohol-related gastritis since he claimed to have consumed excess alcohol while on holiday.

His past medical history includes hyperlipidemia, hypertension, diet-controlled diabetes, previous coronary angioplasty with stenting and previous DC cardioversion for atrial fibrillation. His medication on admission was a beta-blocker, a statin preparation and aspirin. His full blood count, coagulation screen and liver function tests were all within normal limits.

A CT brain scan showed areas of low attenuation in

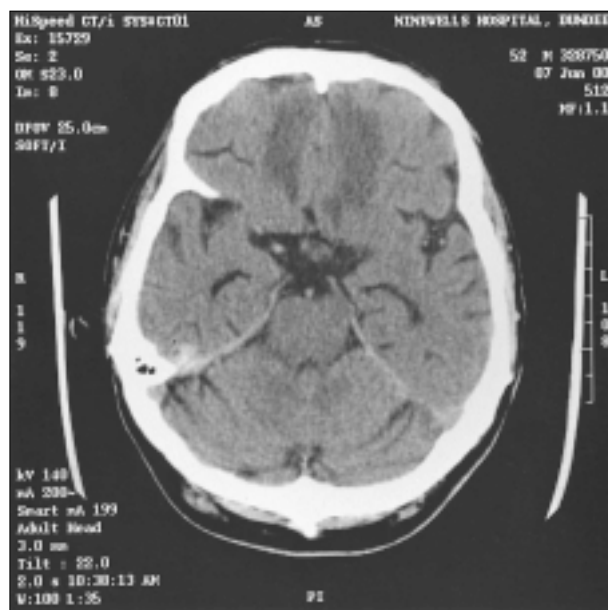

FIGURE 1

CT scan (brain) showing areas of low attenuation in both frontal lobes.

both frontal lobes (Figure 1) affecting the grey and white matter. These were reported as areas of probable ischaemic infarction. There was no evidence of haemorrhage and no enhancement after administering intravenous contrast to suggest that these areas could be due to intracerebral metastases or abscesses.

He became increasingly confused; his Glasgow Coma Scale (GCS) dropped to 10/15. His speech became incomprehensible, he was opening his eyes only in response to painful stimuli but was moving all four limbs voluntarily. There were no focal neurological signs and nothing to suggest that the deterioration in his level of consciousness was due to a preceding epileptic seizure. His GCS improved spontaneously to 15/15 within less than 12 hours but he continued to complain of headache. He was afebrile throughout his admission, with a normal white blood cell count and C-reactive protein (CRP) level. A lumbar puncture was performed to exclude the possibility of infection. Cerebrospinal fluid (CSF) analysis showed 17 white cells and 154 red cells; CSF culture was negative.

He was treated empirically with broad spectrum antibiotics (ceftriaxone and benzylpenicillin) as well as acyclovir and dexamethasone.

Magnetic resonance imaging (MRI) of the brain was performed for further evaluation of the CT scan appearances. The MRI brain scan showed what appeared to be space-occupying lesions in both frontal lobes, arising from both olfactory grooves and extending down to the cribriform plate. The lesions gave a hyperintense signal on T2 weighted images with a surrounding hypointense ring suggestive of haemosiderin (Figure 2). The T1 pre-gadolinium images also showed the lesion as a hyperintense signal (Figure 3). Following intravenous gadolinium there was some anterior enhancement noted. These findings were thought to possibly represent an underlying meningioma arising from the olfactory groove, but were not entirely typical. It was, therefore, felt necessary to perform exploration of the anterior fossa.

He underwent bifrontal craniotomy and exploration of the right olfactory groove. At operation, there was a left linear frontal fracture with haemosiderin staining of both frontal lobes. The mass lesions demonstrated on MRI scan were found at surgery to represent severely contused frontal lobes with swollen olfactory bulbs. The right olfactory bulb was biopsied.

Post-operative recovery was uneventful. Minor residual short-term memory problems and a slight change in personality were evident. He also had evidence of residual right frontalis muscle weakness.

Histological examination of a biopsy from the right olfactory bulb revealed the presence of haematoidin on the leptomeningeal surface. The specimen showed neural tissue disruption, microglial and lymphocytic infiltration and reactive gliosis, all consistent with a reaction to recent

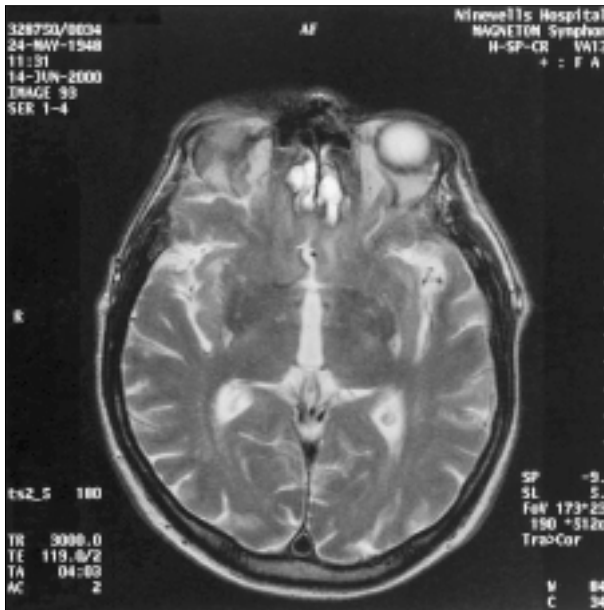


FIGURE 2

Transaxial views of MRI brain, T2 weighted sequences, showing hyperintense signal in the frontal lobes with a surrounding hypointense ring suggestive of haemosiderin.

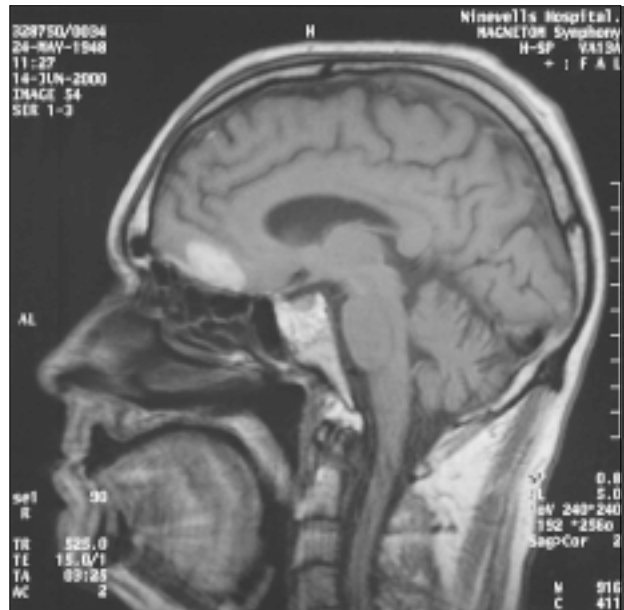


FIGURE 3

Sagittal views, T1 weighted sequences, pre-gadolinium, MRI brain showing high signal intensity areas in the frontal lobe.

trauma and in keeping with olfactory bulb contusion. Staining with vimentin and GFAP (glial fibrillary acidic protein) confirmed the presence of reactive astrogliosis. There was no evidence of a neoplastic process (Figure 4).

DISCUSSION

Because this patient had no previous history of a head injury, his findings on initial imaging were not attributed to underlying contusion. Contusions and lacerations of the frontal lobes are frequent and surgery is only indicated where the lesion behaves as an expanding one causing raised intracranial pressure.¹ Delayed deterioration is an important complication of extensive traumatic bifrontal contusions.²

In this patient, the MRI findings were not entirely typical for a meningioma: the T1 weighted pre-gadolinium

images showed the lesions to be hyperintense rather than hypointense, as one would expect in meningioma. Meningiomas arising from the olfactory groove are common. They may evolve over a period of time and calcify.³ Schwannomas arising from the olfactory groove are extremely rare but have been described.⁴

CONCLUSION

This man presented with a frontal lobe syndrome secondary to traumatic contusions sustained while on holiday. This episode was unknown to him and probably occurred while he was under the influence of alcohol. The diagnosis came to light at surgery when it was evident that the frontal lobe lesions seen on MRI were contusions. This was confirmed by histological examination.




FIGURE 4

Histology of the olfactory bulb showing tissue disruption and gliosis, consistent with a contusion (immunocytochemistry for vimentin x 157).

REFERENCES

- ¹ Papo I, Caruselli G, Scarpelli M *et al.* Mass lesions of the frontal lobes in acute head injuries. A comparison with temporal lesions. *Acta Neurochir (Wien)* 1982; **62(1-2)**:47-72.
 - ² Statham PF, Johnston RA, Macpherson P. Delayed deterioration in patients with traumatic frontal contusions. *J Neurol Neurosurg Psychiatry* 1989; **52(3)**:351-4.
 - ³ Ionel C, Colea A, Milosescu P. Data concerning a case of long-term, asymptomatic, calcified cerebral tumour with late evolution of olfactory meningioma. *Rev Chir Oncol Radiol ORL Oftalmol Stomatol Otorinolaringol* 1980; **25(3)**:219-26.
 - ⁴ Praharaj SS, Vajramani GV, Santosh V *et al.* Solitary olfactory groove schwannoma: case report with review of literature. *Clin Neurol Neurosurg* 1999; **101(1)**:26-8.
-