

# Stridor: an unexpected complication from chemoradiotherapy for anal cancer

<sup>1</sup>MM Moe, <sup>2</sup>C Askill

<sup>1</sup>Locum Consultant; <sup>2</sup>Consultant Oncologist, Oncology Department, Singleton Hospital, Swansea, UK

**ABSTRACT** The treatment of choice for anal cancer is chemoradiotherapy. Skin reaction and bowel symptoms such as tenesmus, diarrhoea and bleeding are common side effects. We report a patient who developed stridor as a result of chemoradiotherapy for anal cancer and discuss the pathogenesis and potential consequences.

**KEYWORDS** Anal cancer, candidiasis, CD4+ lymphocyte, chemoradiotherapy, steroids, stridor

**DECLARATION OF INTERESTS** No conflict of interests declared.

Published online May 2009

Correspondence to MM Moe, Oncology Department, Singleton Hospital, Swansea SA2 8QA, UK

tel. +44 (0)1792 205666

e-mail maungmoe@hotmail.com

## CASE HISTORY

A 67-year-old fit woman started chemoradiotherapy for squamous cell carcinoma of the anal canal, stage T2N0M0. Her medical history included perineal human papilloma virus infection, vulval intraepithelial neoplasia (VIN) stage 3 and cervical intraepithelial neoplasia (CIN) grade 3.

Her radiotherapy tumour dose was 1.8 Gray (Gy) daily, using four separate 6-MeV photon beams directing from anterior, posterior and both sides of the pelvis, Monday to Friday, for a total prescribed dose of 50.4 Gy. Chemotherapy involved intravenous mitomycin C on the first day only, and a continuous infusion of 5-fluorouracil (a dose of 1 g/m<sup>2</sup>/day) for the first four days, to be repeated for four days towards the end of radiotherapy. Dexamethasone, 8 mg daily, was given for the first four days as an antiemetic.

After 28 days and 34.2 Gy of the tumour dose, the patient developed breathing difficulty, especially at night. Clinical examination revealed a very marked stridor and extensive oral thrush. An examination by an ear, nose and throat specialist confirmed severe laryngeal candidiasis with a swollen, inflamed epiglottis blocking the airway (Figure 1). The patient required tracheostomy, intravenous fluconazole, cefuroxime and steroids. The blood test revealed a total lymphocyte count of  $0.2 \times 10^9/l$  (normal:  $1-1.5 \times 10^9/l$ ) and a CD4+ lymphocyte count of only 70/ $\mu l$  (normal: 500–1,500/ $\mu l$ ). The total lymphocyte count just before chemoradiotherapy began was  $1.9 \times 10^9/l$ , which was within normal limits.

The patient was started on co-trimoxazole and acyclovir for the prevention of *Pneumocystis jirovecii* and viral infections respectively. Radiotherapy was resumed seven days later, along with an overdue 5-fluorouracil infusion. However, the patient suffered severe skin desquamation on her buttocks within three days (Figure 2), and the whole treatment was abandoned after a total tumour dose of only 41.4 Gy. Within a few days, the skin reaction

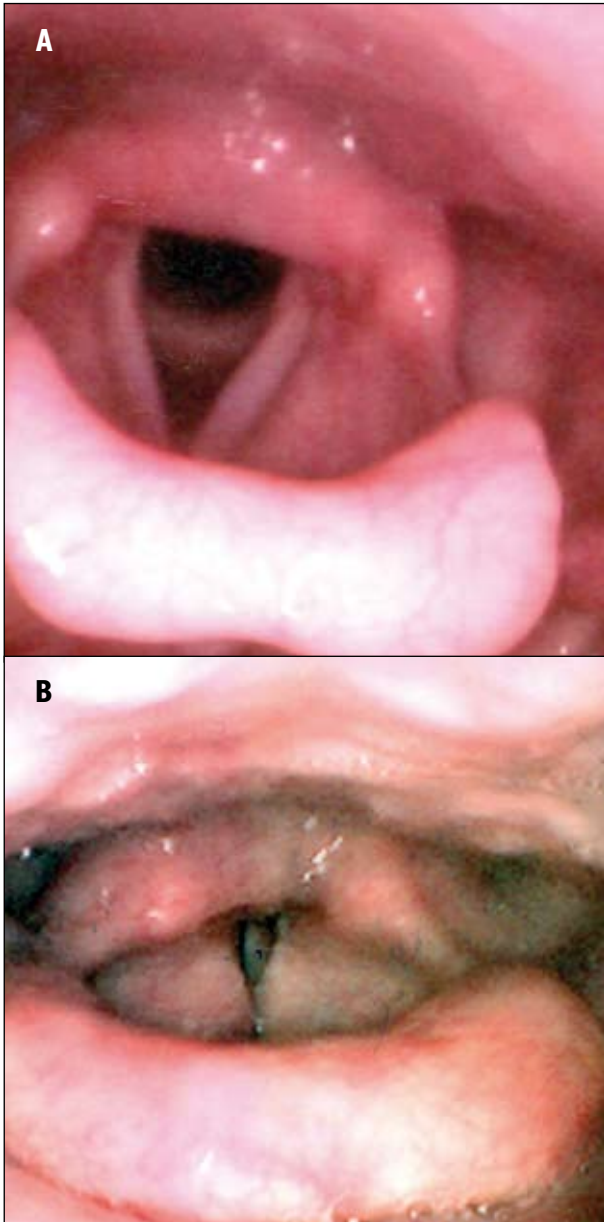
settled, the larynx was clear of candidiasis and the tracheostomy was reversed. The total lymphocyte and CD4+ lymphocyte counts recovered to  $2.0 \times 10^9/l$  and 400/ $\mu l$  respectively within two weeks, and to  $4.8 \times 10^9/l$  and 1,100/ $\mu l$  respectively within four weeks. Haemoglobin, white blood cell, neutrophil and platelet counts remained within normal limits throughout the illness.

## DISCUSSION

Bone marrow depression is one of the known side effects of chemotherapy and pelvic radiotherapy. However, it is unusual to see only lymphopenia while other cell lines remain normal. Mitomycin C is known to cause pancytopenia from delayed bone marrow depression. Steroids cause lymphopenia by interfering with T-lymphocyte proliferation through the inhibition of interleukin-2. Radiotherapy can directly destroy lymphocytes present in the peripheral blood circulation and the bone marrow. The CD4+ lymphocyte count is reportedly more likely to drop when a high-dose steroid is given concomitantly with the radiotherapy.<sup>1-3</sup>

Hughes et al.<sup>1</sup> reported that the CD4+ lymphocyte count dropped below 200/ $\mu l$  in up to 24% of patients with grade 3/4 astrocytoma and oligodendroglioma who received cranial radiotherapy and steroids (dexamethasone), with doses ranging from 4–40 mg daily (mean 23.1 mg/day). A low CD4+ count is also suspected to increase radiotherapy toxicity. Hughes and colleagues reported a higher incidence of hospitalisation for infection among patients with a CD4+ lymphocyte count below 200/ $\mu l$ , compared with above 200/ $\mu l$ , during their cranial radiation for the brain tumours.<sup>1</sup>

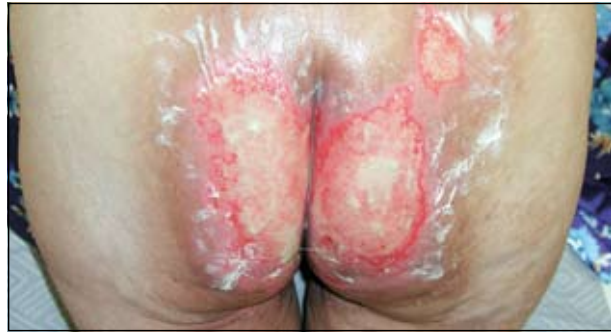During radiotherapy, anal cancer patients with CD4+ lymphocyte counts below 200/ $\mu l$  are more likely to experience severe moist desquamation of the skin, intractable diarrhoea, hospitalisation for infection, treatment breaks and complete cessation of the treatment, compared with those with a count of more than 200  $\mu l$ .<sup>4,5</sup>



**FIGURE 1** Picture of a normal larynx (A) and the larynx of a 67-year-old woman (B) who started chemoradiotherapy for squamous cell carcinoma of the anal canal, stage T2N0M0. After 28 days (34.2 Gy of radiotherapy) the patient suffered breathing difficulty, especially at night. An examination by an ENT specialist confirmed severe laryngeal thrush with an inflamed, swollen epiglottis blocking the airway.

## REFERENCES

- Hughes MA, Parisi M, Grossman S et al. Primary brain tumors treated with steroids and radiotherapy: low CD4 counts and risk of infection. *Int J Radiat Oncol Biol Phys* 2005; 62:1423–6. doi:10.1016/j.ijrobp.2004.12.085
- Harisiadis L, Kopelson G, Chang C. Lymphopenia caused by cranial irradiation in children receiving craniospinal radiotherapy. *Cancer* 1977;40:1102–8. doi:10.1002/1097-0142(197709)40:3<1102::AID-CNCR2820400319>3.0.CO;2-0
- Claude L, Perol D, Ray-Coquard I et al. Lymphopenia: a new independent prognostic factor for survival in patients with whole brain radiotherapy for brain metastases from breast cancer. *Radiotherapy Oncol* 2005; 76:334–9. doi:10.1016/j.radonc.2005.06.004
- Hoffman R, Welton M, Klenske B et al. The significance of pretreatment CD4 count on the outcome and treatment tolerance of HIV-positive patients with anal cancer. *Int J Radiat Oncol Biol Phys* 1999; 44:127–31. doi:10.1016/S0360-3016(98)00528-8
- Peddada AV, Smith DE, Rao AR et al. Chemotherapy and low dose radiotherapy in the treatment of HIV-infected patients with carcinoma of the anal canal. *Int J Radiat Oncol Biol Phys* 1997; 37:1101–5. doi:10.1016/S0360-3016(96)00596-2
- Arnett SJ, Cunningham D, Gallagher J et al. Epidermoid anal cancer: results from the UKCCCR randomised trial of radiotherapy alone versus radiotherapy, 5-fluorouracil, and mitomycin. *Lancet* 1996; 348:1049–54. doi:10.1016/S0140-6736(96)03409-5



**FIGURE 2** Low CD4+ lymphocyte count (<200/ $\mu$ l) is known to increase radiation-induced skin toxicities, and skin desquamation as seen here is an indication for the discontinuation of radiotherapy. Otherwise, a skin graft repair will be required.

Despite this, some studies reported that a disruption of the radiotherapy course or an early stoppage of radiotherapy due to low CD4+ count did not affect the outcome of the treatment, suggesting a lower radiation dose may be sufficient in the presence of a low CD4+ lymphocyte count. However, Claude et al.<sup>3</sup> reported that a lymphocyte count of less than  $0.7 \times 10^9/l$  was a poor prognostic factor for survival, compared with the level above that (hazard ratio 1.9), in patients receiving cranial radiotherapy for brain metastases from breast cancer.

Chemoradiotherapy for anal cancer is known to cause unpleasant, severe side effects and has a treatment mortality rate of 2%,<sup>6</sup> but nobody has been reported to suffer from stridor as a side effect. The risk of opportunistic infection increases with a CD4+ lymphocyte count below 200/ $\mu$ l and the prophylactic antibiotics against *P. jirovecii*, protozoal, viral and fungal infections are required.

## CONCLUSION

Patients on chemotherapy and steroids should be monitored closely for a possible drop in their CD4+ lymphocyte counts during treatment, especially if they are receiving concomitant radiotherapy to the pelvis. This will allow early appropriate action to prevent opportunistic infections from, and severe skin reactions to, radiotherapy.

**Acknowledgement** We thank Dr P Puttasiddaiah for providing the photo of a normal larynx.