

# Was Thomas Wharton Jones FRS, assistant to the infamous Dr Knox, the first to recognise the blood eosinophil?

A Barry Kay<sup>1</sup>

*History & Humanities*



Thomas Wharton Jones (1808–91), described as a ‘genius’ by his famous pupil Thomas Henry Huxley, was an Edinburgh medical graduate. At the age of 19 years he was appointed anatomy demonstrator to the infamous Dr Robert Knox so unwittingly becoming caught up in the Burke and Hare scandal. Escaping to Glasgow, and then to Cork and London, Jones eventually became an outstanding physiologist and ophthalmologist. His seminal observations included scholarly treatises on the vasculature in inflammation together with descriptions of the contractile movement of white blood cells, as well as studies on regeneration and repair, astigmatism and retinitis pigmentosa. He was admitted as a Fellow of the Royal Society in 1840. One of his seminal contributions was his detailed description of ‘granular cells’ in the blood of a large number of animal species, including man. His illustrations suggest strongly these were eosinophils, predating Paul Ehrlich’s definitive studies (using aniline dyes) by 33 years. In later life he was found destitute in his London home and ‘rescued’ by friends and colleagues. William Gladstone was persuaded to give Jones a civil list pension. He lived out the rest of his life in Ventnor on the Isle of Wight.

## Correspondence to:

A Barry Kay  
Sir Alexander Fleming  
Building  
National Heart and Lung  
Institute  
Imperial College  
South Kensington Campus  
London SW7 2AZ  
UK

## Email:

a.b.kay@imperial.ac.uk

**Keywords:** Burke and Hare, eosinophils, ophthalmoscope, Thomas Huxley, Thomas Wharton Jones

**Financial and Competing Interests:** No conflict of interests declared

## Introduction

Thomas Wharton Jones FRS, an Edinburgh medical graduate, was an outstanding physiologist and pioneer ophthalmologist. One of his most distinguished pupils, Thomas Henry Huxley, was to say of him, ‘There is no doubt Wharton Jones was a genius, able to look backwards and forwards, with many and varied interests’.<sup>1</sup> One of his most important works – the first comprehensive description of ‘coarse granular blood cells’ (most likely eosinophils) – predated Paul Ehrlich’s discovery by over 33 years.<sup>2</sup>

Thomas Wharton was the son of Richard Jones, one of the Secretaries for HM Customs for Scotland. He was educated at Stirling, Musselburgh Grammar School and then entered literary classes at the University of Edinburgh in 1822 and began studying medicine a year later, taking his LRCS in 1827. He was then appointed as one of Dr Knox’s demonstrators, the Extramural Lecturer in Anatomy.

## The Burke and Hare scandal

In late November 1827 Burke and Hare brought their first body, a man called ‘Donald’ who had died of natural causes, to Dr Knox’s dissecting rooms at 10 Surgeon Square, explaining that they were offering a ‘subject

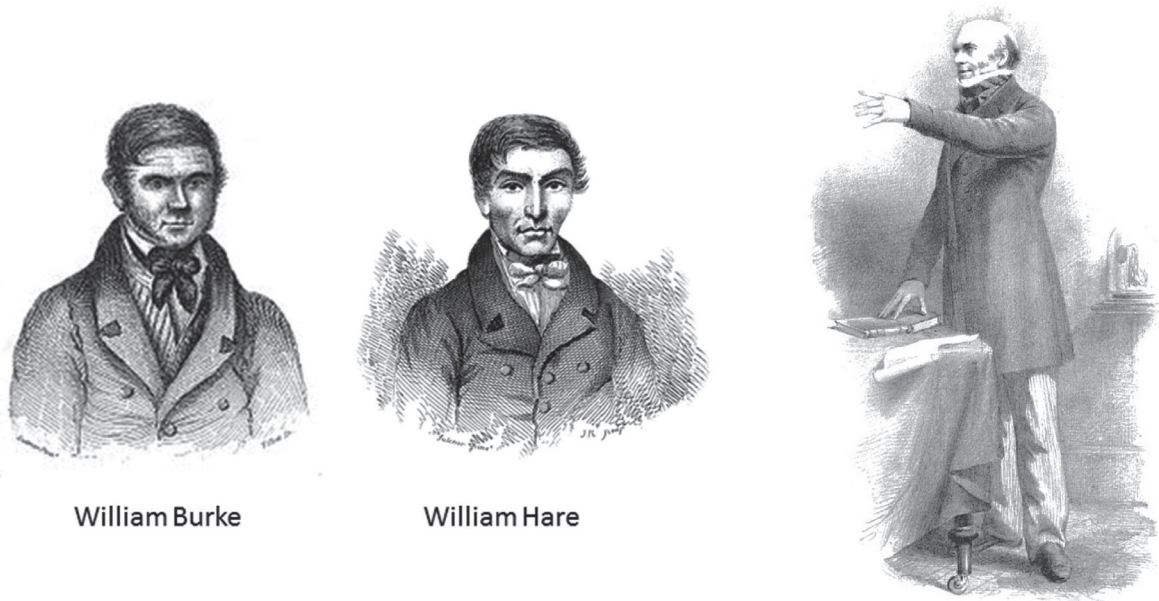
for sale’ (Figure 1). They were met by Dr Knox’s three assistants, one of whom was Jones.<sup>3</sup> Dr Knox was not available and so Burke and Hare were asked to call back after dark. They brought the body back in a sack. Dr Knox arrived from his home in Newington, took a cursory glance at the cadaver, asked no questions as to its origin and proposed that Burke and Hare should receive £7.10s. Jones was instructed to handle the transaction adding that ‘the surgeons would be glad to see them again when they had any other body to dispose of’. Thus Jones was caught up in the scandal and was subpoenaed at the trial, but, fortunately, not called to give evidence. All of Dr Knox’s three assistants were eventually cleared by an investigating committee.

## Appointment in London

Driven from Edinburgh after the trial, Jones migrated to Glasgow where he became associated with William Mackenzie, the ophthalmic surgeon, and with John Burns, under whom he studied embryology. Whilst studying in Glasgow he discovered the germinal vesicle in the mammalian ovum and published his observations in the *Philosophical Magazine* in 1835 and 1837, attracting the attention of the famous Professor Purkinje in Prague.<sup>4</sup>

<sup>1</sup>Emeritus Professor of Allergy and Clinical Immunology, Imperial College, London, UK


**Figure 1** William Burke, William Hare and the anatomist Dr Robert Knox, 1791–1862 (Wikipedia)



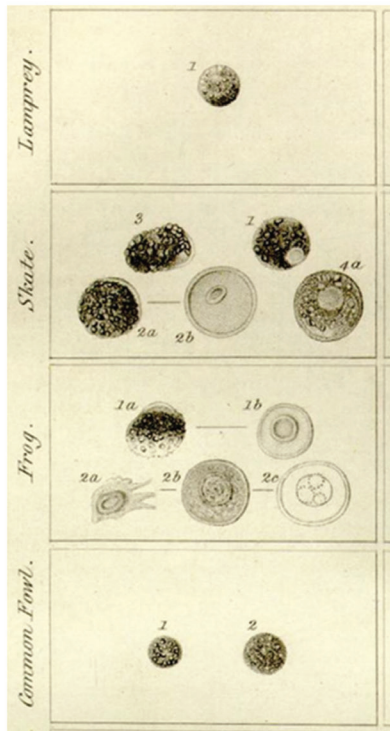
Leaving Glasgow in 1835 Jones went to practise as a specialist in eye and ear diseases in Cork. He then travelled extensively on the continent before returning to England as an ophthalmic surgeon in London. He was appointed a lecturer in Physiology at the Charing Cross Hospital Medical School in 1841 and shortly after was admitted as a Fellow of the Royal Society. In 1851, Jones was appointed Professor of Ophthalmic Medicine and Surgery at University College, London.

His time in London was extraordinarily productive (Figure 2). Amongst his seminal contributions were his essays on 'The State of Blood Vessels in Inflammation', descriptions of degeneration on divided nerves, demonstrating that the bat wing was furnished with valves, observations on the caudal, lymphatic, heart of the eel, papers on the healing process, as well as the contents of the hepatic ducts and the anatomy of the choroid gland of the fishes eye.<sup>1</sup>

**Figure 2** Thomas Wharton Jones (1808–91). On the left is a daguerreotype (date unknown) showing Jones with the eminent physician, Dr John Webster FRS (1795–1876; seated) (reproduced with permission from the Victoria and Albert Museum). On the right is a photograph of Jones taken later in life (Wikipedia, Creative Commons Attribution 4.0 International license)



**Figure 3** Jones's drawing of granular cells from the lamprey, skate, frog and fowl together with legends to figures from his original article in the *Philosophical Transactions*.<sup>6</sup> They bear a remarkable resemblance to eosinophils. Jones believed, incorrectly, that there were three phases of development of blood corpuscles, the 'granule cell' phase, the 'nucleated cell' phase and the 'free cellaeform' phase. Only drawings of the so-called granules phase are reproduced



#### LAMPREY.

Though it was not considered necessary to describe the blood-corpuscles of the Lamprey particularly, a few figures of them are given for the sake of comparison.

#### First Phase.—Granule-cell.

Fig. 1. Granule-cell somewhat distended by the action of water.

#### SKATE.

#### First Phase.—Granule-cell.

Fig. 1. A granule-cell in the coarsely granular stage, presenting a clear spot on one side indicating the place of the nucleus.

Fig. 2 a. Granule-cell distended by the action of water.

Fig. 2 b. The same cell after the action of acetic acid. The granules have been dissolved and a cellaeform nucleus brought into view.

Fig. 3. Granule-cell in the act of changing its shape, with movements of its granules, as described, par. 30 *et seq.*

Fig. 4 a. Granule-cell in the finely granular stage after the action of water.

#### FROG.

#### First Phase.—Granule-cell.

Fig. 1 a. Granule-cell in coarsely granular stage, and in the act of changing its shape (par. 59.).

#### COMMON FOWL.

#### First Phase.—Granule-cell.

Fig. 1. Granule-cell, coarsely granular stage.

Fig. 2. Granule-cell, finely granular stage.

## Discovery of 'blood granular cells' (eosinophils)

Paul Ehrlich's techniques, published between 1879 and 1880, for staining blood films using coal tar dyes, and his method of differential blood cell counting, ended years of speculation regarding the classification of white cells.<sup>5</sup> Acidic and basic dyes had allowed him to recognise eosinophil and basophil granules, respectively; work which was a direct continuation of his discovery of the tissue mast cell described in his doctoral thesis. However, 33 years earlier Jones recognised 'granular cells' in the blood and clearly documented his findings.<sup>6</sup> These were likely to be Ehrlich's eosinophils.

During the 1840s Jones was one of many investigators curious to know whether the colourless (white) cells actually passed through the intact walls of the capillaries. He was able to demonstrate that they showed contractile movements of an amoeboid nature. It was later, in 1863, that von Recklinghausen, Virchow's assistant at the Charité in Berlin, showed conclusively that they passed through capillaries by a combination of contractility and locomotion.<sup>7</sup>

On 19 June 1845 Jones read his seminal work on 'The Blood-corpuscle considered in its different phases of Development in the Animal series' to the Royal Society. Although this was essentially a description of different types of blood cells in the blood of various animals and man, Jones was clearly intrigued by cells containing granules. He first describes these in the blood of the skate, "(the

corpuscle is composed of an agglomeration of granules surrounded by a cell-membrane. The granules are clear and strongly attract the light. They measure about  $1/20,000$  of an inch in diameter, but it is to be remarked, and at another time more or less fused together, as if they had been granules of quicksilver. In consequence of the structure under consideration, I propose to designate it by the name 'granule blood-cell'" (Figure 3).

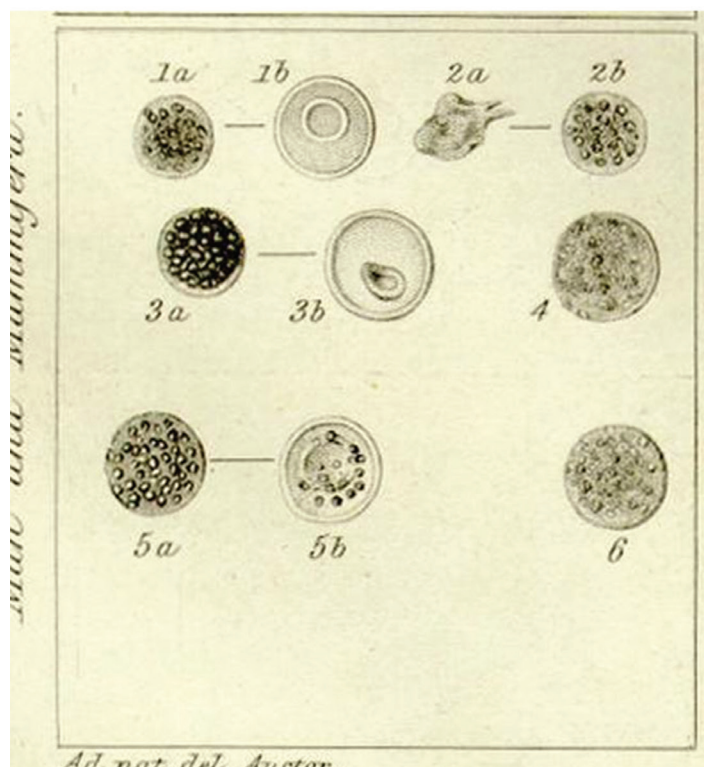
In an attempt to distend the cells to examine the granules more closely Jones studied the effects of treatment with either water or dilute acetic acid. He wrote, 'I have watched individual cells during the action of the acid on them, and have seen one granule disappearing after another in the most beautiful and striking manner, until the nucleus came into view'. After treatment with acetic acid Wharton Jones estimated that the diameter of the human granule blood-cell to be about  $1/2,400$  of an inch in diameter compared to  $1/3,650$  of an inch without treatment.

As well as red corpuscles Jones's article also mentions finely granular (presumably neutrophils), as well as coarse granular, cells. He examined blood from a large number of species, including the lamprey, frog, fowl, horse, elephant and man (Figure 4).

When considering the corpuscles of *Man and the Mammifera* he writes, 'Both coarsely and finely granule-cell may be recognised. In human blood they in general become speedily collapsed after the blood is drawn, and some, especially those in the finely granule stage, may be



**Figure 4** Jones's drawing of granular cells from man, horse and elephant together with legends to figures from his original article in the *Philosophical Transactions*.<sup>6</sup> The effects of distention of the cells with either water or acetic acid are shown. The untreated cells bear a remarkable resemblance to eosinophils



MAN AND THE MAMMIFERA.  
First Phase.—Granule-cell.  
Fig. 1 a. The granule-cell of human blood in its coarsely granular stage distended by water.  
Fig. 1 b. The same, after being acted on by acetic acid. The granules have been dissolved and a single cellaeform nucleus disclosed.  
Fig. 2 a. The granule-cell of human blood in its finely granular stage in a state of collapse.  
Fig. 2 b. The same, distended by water.  
Fig. 3 a. The granule-cell, coarsely granular stage, of the blood of the Horse.  
Fig. 3 b. The same, after being acted on by acetic acid.  
Fig. 4. The granule-cell, finely granular stage, of the blood of the Horse.  
Fig. 5 a. The granule-cell, coarsely granular stage, of the blood of the Elephant.  
Fig. 5 b. The same, in process of being acted on by acetic acid.  
Fig. 6. The granule-cell, finely granular stage, of the blood of the Elephant.

seen on careful inspection shooting out processes like the same cells in the blood of the frog'. Thus, Jones was also recording, possibly for the first time, that cells move by amoeboid movement.

It is remarkable that Jones was able to describe cells and their features with only primitive optics – a Ross compound microscope with a 1/8 inch objective – and without the use of an anticoagulant. Inevitably he observed many artefacts as a result of both his treatments and simple drying out. These he over interpreted, speculating incorrectly that the coarse granular cells were a stage in development of the finely granular cells. His contention that there were three phases of development of blood corpuscles – the 'granule cell' phase, the 'nucleated cell' phase and the 'free cellaeform' phase – would not, of course, be accepted today.

These errors of interpretation are perhaps understandable. 'Wet', unfixed preparations, without anticoagulants or dyes with affinity for cell granules and the nuclei, are subject to artefacts and cannot differentiate between various leucocyte types. Modern haematology techniques, however, enable the fine structure of the nucleus and cytoplasm to be visualised, and metachromatic stains clearly differentiate acidic, basic and neutral granules.

One question is whether basophils as well as eosinophils were being observed since basophils are also heavily granulated and Jones would not have been able to distinguish between these two cell types. This possibility cannot be excluded with

certainty, although in the healthy blood there are about 30–40 eosinophils for every basophil.

### Earlier documentation of granular cells in pathological fluids

There had been earlier recordings of granular cells in pathological fluids, but not in healthy blood. Jones states in a footnote, "the name 'granule-cell' I have borrowed from Professor Vogel in Gottingen, who first employed it to designate a form of cell which is developed in inflammatory exudations". Julius Vogel (1814–80) was also a skilful microscopist and the author of a pioneering book on the *Pathological Anatomy of the Human Body* (1847).<sup>8</sup> He had described granular cells in certain inflammatory states that 'are for the most part round, but sometimes elongated or even angular ... it is difficult to distinguish whether they (the granules) are on the surface or in the interior of the cell'.

Even before Vogel the Belgium clinician and scientist Gottlieb (Théophile) Gluge (1812–98), a pioneer medical researcher and personal physician to the King of Belgium, also examined diseased tissue microscopically. His major work was the *Atlas der Pathologischen Anatomie* (1843) in which he described 'inflammatory globules', a term he preferred to 'granular cells'.<sup>9</sup> These cells were observed not only in inflammatory exudates but also in colostrum and the ovary. They resembled eosinophils but, unlike Jones's excellent drawings, the quality of Gluge's illustrations were poor. Thus Jones's observations, unlike Gluge and Vogel, were conclusive in the sense that

**Figure 5** Extracts of a letter from Thomas Huxley to Thomas Wharton Jones saying how pleased he is that the Prime Minister recognises his achievements and has granted him a pension, and also wishing Jones a happy retirement (origin unknown)

Grassmere, Westmoreland  
Sep. 12. 1881

My dear Mr Wharton Jones

I write to say how  
very glad I am to hear  
that the Prime Minister  
has recognised your  
successful position by  
recommending you to the

peaceful retirement to which  
you appear to be well adapted  
enough to begin sometime  
to long

Yours  
Truly  
Thomas Huxley

material was from healthy living tissue, i.e. blood, and his descriptions were detailed and covered a range of species including man.

### The ophthalmoscope 'error'

At the time he was writing his important articles on blood corpuscles and inflammation, Jones pursued his other career as a successful ophthalmologist, and in 1847 published a distinguished treatise on *Ophthalmic Medicine and Surgery* (1846). He had made several original observations in the field, for example, that astigmatism was due to a fault in the curvature of the cornea rather than an error in the lens. He also observed the frequent association of retinitis pigmentosa with deaf-mutism and other neurological disorders.

Sadly, Jones 'missed out' on the ophthalmoscope. In 1847 his opinion was sought by a colleague Charles Babbage who had constructed a primitive instrument – a handheld mirror with the silvering crudely scraped off at one point to form a hole through which one could look.<sup>10</sup> Jones was dismissive of the device and Babbage lost interest. What Babbage had missed in his design was the need for a concave lens between the observer's eye and the back of the mirror to correct the convergent rays from the patient's retina. Thus, but for the addition of a 4 or 5 dioptric concave lens, Babbage, rather than the German, Hermann

von Helmholtz, would have been credited with the invention that revolutionised modern ophthalmology.

### His appearance and character

In a brief biography by Sir Rickman Godlee<sup>11</sup> Jones is described as a 'diminutive figure, clad in rusty broad-cloth, his quaint pallid face, piercing eyes and the wisp of straight iron grey hair hanging down on each side from below his skull cap' (Figure 2). He had enormous energy but he was rather unsociable, absorbed in his work and had few friends. He felt that much of his work was unappreciated and that dissertations by colleagues that he considered lesser than his had received credit they did not deserve. This embittered his life and may have interfered with even greater success. He made enemies of those who might have done much to help him. It was also not to his credit that he was fiercely critical of Darwin's theory of evolution dismissing it as, 'mere conceit unsanctioned by science'. He published a book in 1876 propounding this view.<sup>12</sup>

### Final days

Despite his eminence and the respect of colleagues Jones became somewhat of a recluse and during the week of the great blizzard of 1881 was found by his friend Sir John Tweedy in his rooms in Harley Street virtually dying of starvation and 'the picture of destitution'. Without Jones's

knowledge Tweedy organised a rescue fund that was paid in sovereigns rather than cheques into his bank account to maintain anonymity. Later, Thomas Huxley went to Gladstone who was persuaded that Jones should head the next civil list (Figure 5). A pension was also granted by the Royal Society at the insistence of the President, again without Jones knowing who his benefactors were. Jones lived out his life in Ventnor on the Isle of Wight where he died, unmarried, on 7 November 1881.

In summary Thomas Wharton Jones was a noteworthy Edinburgh medical graduate. Tainted by the Burke and Hare scandal early in his career, probably through inexperience and misguided loyalty to Dr Knox, he managed to distance himself from the affair going on to pursue a highly productive clinical scientific career in London where he made seminal contributions in the fields of physiology and ophthalmology. His early description of 'granular cells' (years later identified by Paul Ehrlich as 'eosinophils') was one of his more outstanding achievements. ①

## References

- 1 Jones, Thomas Wharton (1801–1891). Parr's Lives of the Fellows Online. Royal College of Surgeons 2012. <https://livesonline.rcseng.ac.uk/biogs/E002393b.htm> (accessed 01/06/18).
- 2 Kay AB. The early history of the eosinophil. *Clin Exp Allergy* 2015; 45: 575–82.
- 3 Edwards OD. *Burke and Hare*. Edinburgh: Birlinn Ltd; 2010. pp. 80–2.
- 4 Jones TW. On the first changes in the ova of the mammifera in consequence of impregnation and of the mode of origin of the chorion. *Phil Trans* 1837; 339–46.
- 5 Ehrlich P. Beiträge zur Kenntnis der granulierten Bindegewebszellen und der eosinophilen Leukocythen. *Archiv für Anatomie und Physiologie, Physiologische Abteilung* 1879; 166–9.
- 6 Jones TW. The blood corpuscle considered in its different phases of development in the animal series. Memoir 1, vertebrata. *Philos Trans R Soc Lond* 1 1846; 63–87.
- 7 Von Recklinghausen FD. Ueber Eiter - und Bindegewebskörperchen. *Virchow's Archiv für pathologische Anatomie und Physiologie, und für klinische Medizin Berlin* 1863; 28: 157–97.
- 8 Vogel J. *The Pathological Anatomy of the Human Body*. Translated from German. Philadelphia: Blanchard and Lea; 1847.
- 9 Gluge G. *Atlas der Pathologischen Anatomie*. Translated from French. Philadelphia: Blanchard and Lea; 1853.
- 10 Keeler CR. Babbage the unfortunate. *Br J Ophthalmol* 2003; 88: 730–2.
- 11 Godlee RJ. British Masters of Ophthalmology Series: 12.- Thomas Wharton Jones. *Br J Ophthalmol* 1921; 5: 45–156.
- 12 Jones TW. *Evolution of the human race from apes, and apes from lower animals, a doctrine unsanctioned by science*. London: Smith, Elder and Co.; 1876.