

MRSA vertebral discitis managed successfully using linezolid as a component of an oral antibiotic regimen

¹D Inverarity, ²J Coia, ³G O'Neill, ⁴R MacTier

¹Clinical Research Training Fellow in Medical Microbiology, Department of Medical Microbiology, ²Consultant Microbiologist, Department of Medical Microbiology, ³Consultant Radiologist, Department of Radiology, ⁴Consultant Renal Physician, Department of Renal Medicine, Glasgow Royal Infirmary, Glasgow, Scotland

ABSTRACT We describe a 71-year-old lady with end-stage renal failure on haemodialysis who developed vertebral discitis due to MRSA. She was intolerant of glycopeptide antibiotics and was treated successfully with oral linezolid for four weeks followed by oral combination therapy with doxycycline and fusidic acid for two weeks. Her antibiotic management and her clinical course is described, and we discuss the usefulness of the above antibiotics to treat MRSA infections affecting bone and vertebral discs in patients with renal failure.

KEYWORDS Discitis, linezolid, methicillin resistant *Staphylococcus aureus*

LIST OF ABBREVIATIONS C-Reactive protein (CRP), computed tomography (CT), methicillin resistant *Staphylococcus aureus* (MRSA), minimum inhibitory concentration (MIC), National Committee of Clinical Laboratory Standards (NCCLS)

DECLARATION OF INTERESTS No conflict of interests declared.

Published online April 2006

Correspondence to Dr D Inverarity, Clinical Research Training Fellow, Division of Infection and Immunity, Institute of Biological and Life Sciences, Glasgow Biomedical Research Centre, University of Glasgow, 120 University Place, Glasgow, G12 8TA

tel. +44 (0)141 330 4642

fax. +44 (0)141 330 4600

e-mail

d.inverarity.1@research.gla.ac.uk

CASE REPORT

A seventy-one-year-old female presented with one week of nausea and anorexia associated with a dry cough, breathlessness and orthopnoea. In addition she had low back pain that was severe and exacerbated by movement.

Her past medical history included end-stage renal failure secondary to analgesic nephropathy and Type IV Renal Tubular Acidosis. She had been established on haemodialysis two years previously, but her fistula had clotted and was dialysed via a temporary central venous catheter. Her other co-morbidities included a stroke, a clipped cerebral aneurysm, paroxysmal ventricular tachycardia, atrial fibrillation, chronic obstructive pulmonary disease, psoriasis, gout, chronic gastritis and chronically abnormal liver function tests associated with a dilated bile duct. She required regular iron and erythropoietin infusions and had a previous severe allergic reaction to vancomycin. Nasal colonisation with MRSA had been identified six months earlier on routine surveillance cultures.

On admission she was febrile, pale, hypertensive and the site of her internal jugular dialysis catheter was erythematous with an associated purulent discharge. She was started empirically on intravenous teicoplanin for treatment of a dialysis line site infection and the dialysis line was removed. Forty-eight hours after admission, blood cultures were found to be growing staphylococci

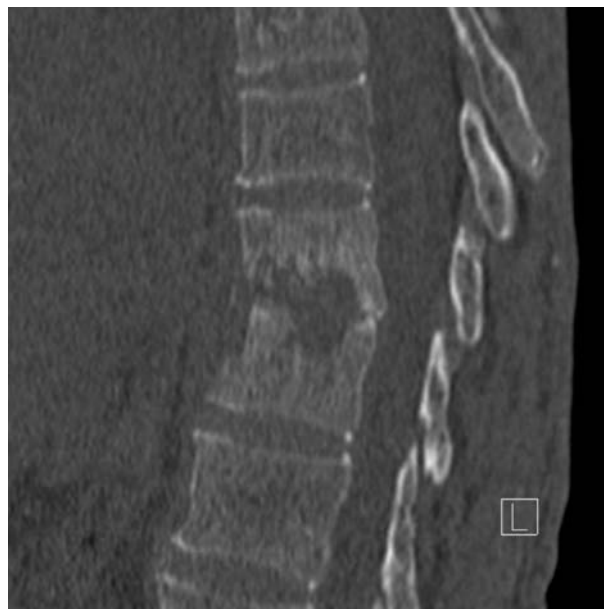

FIGURE 1 A lateral view of a spiral CT scan of the lower thoracic spine showing infective discitis at the T9/10 level with destruction of the vertebral endplates above and below.

which were identified as MRSA (further identified as the epidemic strain MRSA16) which was sensitive to fusidic acid, gentamicin, rifampicin and tetracycline by disc sensitivity testing using NCCLS criteria and sensitive to linezolid (MIC = 1.5mg/L) and teicoplanin (MIC = 1.0mg/L) using E-tests (AB Biodisk, UK). Oral fusidic acid was added to the teicoplanin. In the second week of

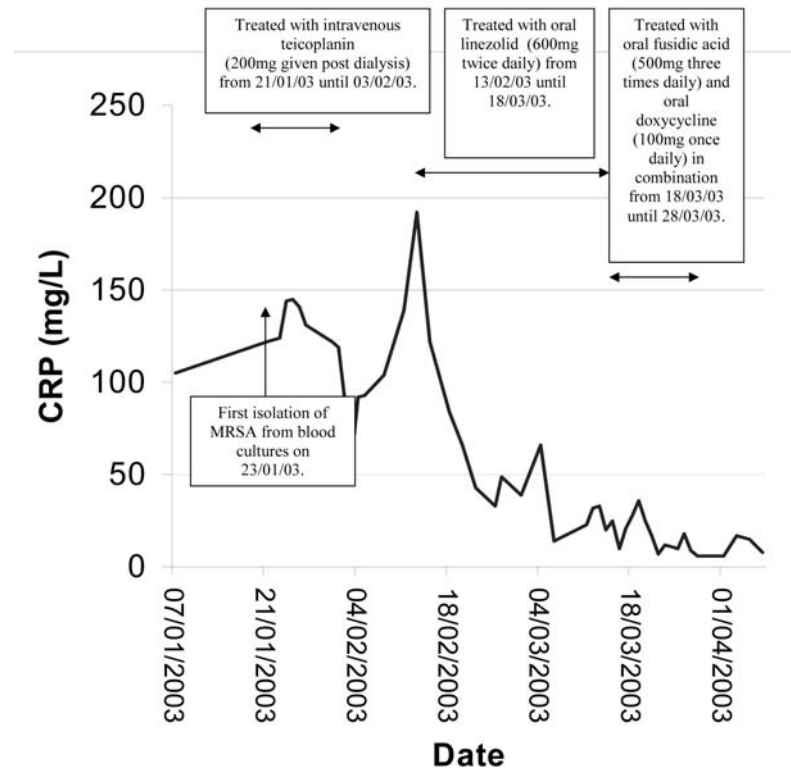


FIGURE 2 The response of CRP to treatment with antibiotics. The first isolate of MRSA from blood cultures was on 23/01/03. Intravenous teicoplanin (200 mg) was administered from 21/01/03 until 03/02/03 after each dialysis session. The CRP rose substantially after treatment with teicoplanin was discontinued. Linezolid was administered orally (600 mg twice daily) from 13/02/03 until 18/03/03 with a substantial fall in CRP and improvement in symptoms. Oral doxycycline (100 mg once daily) and oral fusidic acid (500 mg three times daily) were administered concurrently from 18/03/03 until 28/03/03 while the CRP returned to a normal baseline.

treatment she developed a global, erythematous, itchy eruption that was diagnosed as a drug reaction due to teicoplanin and this was discontinued.

A CT scan of her thoracic spine, performed to investigate her low back pain, showed destruction of the inferior aspect of the T9 vertebral body and the superior aspect of the T10 vertebral body and discitis at this level (see Figure 1). A CT guided biopsy of the disc grew MRSA with identical antibiotic sensitivities to that isolated from blood cultures.

Treatment was commenced with oral linezolid and was well tolerated, continuing for four weeks without any adverse effect. Her CRP measurements fell on therapy as displayed in Figure 2. After four weeks of linezolid she was switched to combination therapy with oral doxycycline and oral fusidic acid because of concerns regarding the continuation of linezolid past the recommended treatment course duration of fourteen days. Fusidic acid and doxycycline were again tolerated without adverse effects and her CRP returned to the normal range.

A CT scan of the thoracic spine was repeated when antibiotic therapy stopped and showed destruction of the

end plates of the T9 and T10 vertebrae with loss in vertebral height resulting from a horizontal fracture through the inferior aspect of the T9 vertebral body. These features were compatible with a recent infective discitis.

A further episode of MRSA bacteraemia with an associated raised CRP occurred seventeen weeks after finishing antibiotics and required a subsequent course of linezolid to which she responded promptly.

DISCUSSION

Vertebral discitis and osteomyelitis are recognised complications of *Staphylococcus aureus* bacteraemia which are more common in patients requiring renal replacement therapy,^{1, 2} possibly due to the immunosuppressive effect of uraemia.² Treatment with vancomycin is recommended as the first line antibiotic in haemodialysis patients for sepsis due to MRSA³ although vancomycin monotherapy has been associated with a poor outcome in the management of vertebral osteomyelitis.⁴ Where there is a suggestion of MRSA osteomyelitis, effective oral combination therapy should follow initial intravenous treatment with vancomycin.¹ As our patient was intolerant of glycopeptides, alternative suitable antibiotic options

were limited. We are only aware of one published instance of linezolid, prescribed to treat vertebral discitis due to MRSA, and this patient had been treated initially with two weeks of intravenous vancomycin before starting linezolid.⁵

Linezolid is an oxazolidinone antibiotic which is primarily excreted unchanged through the kidneys^{6,7} but also by a non-renal route. It inhibits the initiation of protein synthesis by binding to bacterial 23S ribosomal RNA and is active against predominantly Gram positive bacteria including multiply resistant species.⁷

Having 100% bioavailability, it is as effective when given orally as when given intravenously.⁶ Linezolid penetrates bone and can be given in renal failure.⁵ Around 30% of a dose is eliminated in a three hour dialysis treatment⁸ but no dose adjustments are required in dialysis patients⁸ although it has been suggested that a dose should be given immediately post-dialysis.⁷ The main adverse effects of linezolid are haematological with anaemia or, more commonly, thrombocytopenia occasionally developing when used for longer than fourteen days.^{6,9} We used linezolid for four weeks without any thrombocytopenia. Although our patient required a blood transfusion during this time, her anaemia was attributed to her chronic renal failure and chronic gastritis and not the use of linezolid.

Fusidic acid is bactericidal against *S. aureus*, attains high serum levels and is active in pus and bone where it achieves high levels which are above the minimum inhibitory concentrations for most infections.¹⁰ There is little excretion of fusidic acid in the urine as it is mainly

excreted in bile and it is 87–94 % protein bound in plasma.¹¹ It has been well established as being safe in patients requiring dialysis without requiring dose reductions,¹¹ although very rarely it has been cited as a cause of worsening renal function.¹²

Doxycycline, unlike other tetracyclines, is safe in renal failure. Although 30–40% is eliminated via the kidneys,¹³ its excretion is independent of renal function as increased enterohepatic metabolism can compensate for decreases in renal excretion.¹⁴ There appears to be no accumulation in plasma of doxycycline in dialysis patients.¹³ Doxycycline also has the advantage of having a long plasma half-life enabling low, once-daily doses to be given. It has anti-staphylococcal activity even in many strains which are methicillin resistant and it also penetrates synovium and bone.¹³

CONCLUSION

We describe the successful management of MRSA vertebral discitis, which did not require surgical intervention, and was treated with an oral regimen (which was suitable for a patient who was dependent on haemodialysis) of linezolid for four weeks and then two weeks of combination therapy with fusidic acid and doxycycline.

ACKNOWLEDGEMENTS

We would like to thank the Scottish MRSA Reference Laboratory for the confirmatory identification and molecular typing of the MRSA isolate.

REFERENCES

- 1 Torda AJ, Gottlieb T, Bradbury R. Pyogenic vertebral osteomyelitis: analysis of 20 cases and review. *Clin Infect Dis* 1995; **20**:320–8.
- 2 Nicholls A, Edward N, Catto GRD. Staphylococcal septicaemia, endocarditis, and osteomyelitis in dialysis and renal transplant patients. *Postgrad Med J* 1980; **56**:642–8.
- 3 Golper TA, Schulman G, D'Agata EMC. Indications for vancomycin in dialysis patients. *Semin Dial* 2000; **13**:389–92.
- 4 Gelfand MS, Cleveland KO. Vancomycin therapy and the progression of methicillin-resistant *Staphylococcus aureus* vertebral osteomyelitis. *South Med J* 2004; **97**:593–7.
- 5 Melzer M, Goldsmith D, Gransden W. Successful treatment of vertebral osteomyelitis with linezolid in a patient receiving hemodialysis and with persistent methicillin-resistant *Staphylococcus aureus* and vancomycin-resistant enterococcus bacteraemias. *Clin Infect Dis* 2000; **31**:208–9.
- 6 Moellering RC. Linezolid: The First oxazolidinone antimicrobial. *Ann Intern Med* 2003; **138**:135–42.
- 7 Paladino JA. Linezolid: An oxazolidinone antimicrobial agent. *Am J Health-Syst Pharm* 2002; **59**:2413–25.
- 8 Bailey EM, Faber MD, Nafziger DA. Linezolid for treatment of vancomycin-resistant enterococcal peritonitis. *Am J Kidney Dis* 2001; **38**:E20.
- 9 Gerson SL, Kaplan SL, Bruss JB et al. Hematologic effects of linezolid: summary of clinical experience. *Antimicrobial Agents and Chemotherapy* 2002; **46**:2723–6.
- 10 Lautenbach EEG, Robinson RG, Koornhof HJ. Serum and tissue concentrations of sodium fusidate in patients with chronic osteomyelitis and in normal volunteers. *SAJS* 1975; **13**:21–32.
- 11 Brown NM, Reeves DS, McMullin CM. The pharmacokinetics and protein-binding of fusidic acid in patients with severe renal failure requiring either haemodialysis or continuous ambulatory peritoneal dialysis. *J Antimicrob Chemother* 1997; **39**:803–9.
- 12 Davies JP, Alderman PA. Acute renal failure in association with fusidic acid. *Int J Clin Pract* 1997; **51**:264.
- 13 Saivin S, Houin G. Clinical pharmacokinetics of doxycycline and minocycline. *Clinical Pharmacokinetics* 1988; **15**:355–66.
- 14 Heaney D, Eknoyan G. Minocycline and doxycycline kinetics in chronic renal failure. *Clinical Pharmacology and Therapeutics* 1978; **24**:233–9.