

## OCCIPITAL EPILEPSY AND MIGRAINE

*N. Gordon, Consultant Paediatric Neurologist, Manchester Children's Hospitals: Retired*

An increased incidence of epilepsy is recognised in those suffering from migraine, and of migraine in those with epilepsy. Both migraine and occipital epilepsy can present with visual aura and then difficulties with diagnosis can occur. Occipital epilepsy is defined by its symptoms, the EEG and other evidence of its site of origin, and migraine by the characteristics of the headaches. In migraine the visual aura consists of blurred vision, coloured lights, fortification spectra, negative scotomata and hemianopia, while in occipital epilepsy there may be transient loss of vision or simple visual hallucinations of colours or geometric shapes. To further complicate the issue, these partial seizures may be followed by headaches and vomiting suggestive of migraine. In 1879 Gowers reported a patient with auras consisting of a polished plate over his breast, a golden serpent and transient blindness. The initial diagnosis was classical migraine, but this condition responded to treatment with bromides; at autopsy an occipitotemporal tumour was found. Then the diagnosis of the auras was changed to that of epilepsy.<sup>1</sup> Even after more than 100 years the differential diagnosis can still remain difficult, and is still mainly a clinical one.

First, the different types of occipital epilepsy are considered and then some of the factors which may link them to migraine are discussed.

## OCCIPITAL EPILEPSY

Different types of idiopathic seizures may arise in the occipital lobes. The main arguments in favour of subdividing

them into separate syndromes are their variable prognoses and responses to anti-epileptic drugs.<sup>2</sup> Other syndromes with somewhat similar titles may lead to a degree of confusion, especially when they are referred to by their acronyms.

## VARIETIES OF OCCIPITAL EPILEPSY

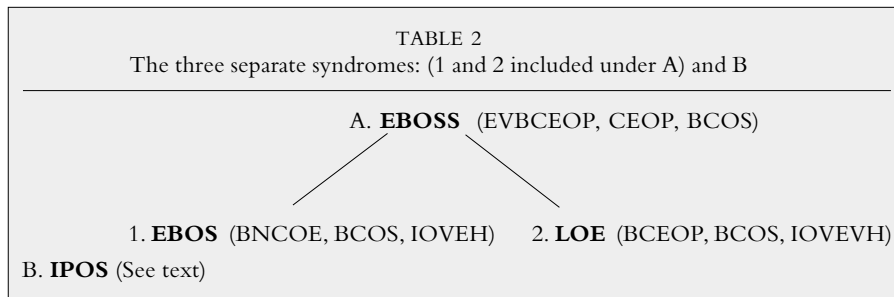
The main differences between Early-Onset Benign Childhood Occipital Seizures (EBOS) and Late-Onset Childhood Idiopathic Occipital Epilepsy (LOE) are well established;<sup>10</sup> both are examples of the Early Benign Childhood Seizure Susceptibility Syndrome (EBOSS). Oguni *et al.*<sup>12</sup> supports the claims of Panayiotopoulos<sup>9</sup> that the Early-Onset Variant of Benign Childhood Epilepsy with Occipital Paroxysms (EVBCEOP) is identical with the Early-Onset Benign Occipital Seizure Susceptibility Syndrome (EBOSS), but different from the classical Benign Childhood Epilepsy with Occipital Paroxysms (BCEOP), otherwise known as the Late-Onset Variety (LOE). Oguni *et al.*<sup>13</sup> do feel that as the early-onset variety has such a wide clinical spectrum, further studies will be needed to clarify its borders. Benign Nocturnal Childhood Occipital Epilepsy (BNCOE) seems to be the same as Early-Onset Benign Childhood Occipital Seizures (EBOS) (Table 1).

Therefore three syndromes warrant separate consideration: Early and Late Onset Benign Childhood Occipital Seizures (both examples of benign childhood occipital seizures), and Idiopathic Photosensitive Occipital Seizures (IPOS) (Table 2).

TABLE 1  
Syndromes associated with seizures of occipital origin

<b>CEOP</b>	Childhood Epilepsy with Occipital Paroxysms (1989) <sup>3</sup>
<b>BCEOP</b>	Benign Childhood Epilepsy with Occipital Paroxysms (1994) <sup>4</sup>
<b>BNCOE</b>	Benign Nocturnal Childhood Occipital Epilepsy (1995) <sup>5</sup>
<b>ILRRE</b>	Idiopathic Localization-Related Reflex Epilepsy (1995) <sup>6</sup>
<b>EBOSS</b>	Early-Onset Benign Occipital Seizure Susceptibility Syndrome (1997) <sup>7</sup>
<b>BEOP</b>	Benign Epilepsy with Occipital Paroxysms (1997) <sup>8</sup>
<b>BCOS</b>	Benign Childhood Occipital Seizures (1998) <sup>9</sup>
<b>EBOS</b>	Early-Onset Benign Childhood Occipital Seizures (1999) <sup>10</sup>
<b>LOE</b>	Late-Onset Childhood Idiopathic Occipital Epilepsy (1999) <sup>10</sup>
<b>IOEVH</b>	Idiopathic Occipital Epilepsy with Visual Hallucinations (1999) <sup>11</sup>
<b>BECT</b>	Benign Childhood Epilepsy with Centrottemporal EEG Foci (1999) <sup>12</sup>
<b>EVBCEOP</b>	Early-Onset Variant of Benign Childhood Epilepsy with Occipital Paroxysms (similar to EBOSS and EBOS, but different from BCEOP, the late-onset variety LOE) (1999) <sup>12</sup>
<b>IPOS</b>	Idiopathic Photosensitive Occipital Seizures

The dates of the various publications are included to show the order in which the different titles were given to the syndromes as knowledge of the variations between them increased.



The commonest type of occipital epilepsy is the Early-Onset Benign Childhood Occipital Seizures (EBOS), a form of epilepsy akin to the benign Rolandic epilepsy of childhood, first delineated by Panayiotopoulos in 1989.<sup>3</sup> Panayiotopoulos,<sup>10</sup> in his description of these attacks, states that ictal vomiting is common, and so is deviation of the eyes, visual hallucinations and blindness, but headache is a rare occurrence. Consciousness is often impaired and automatisms can occur. The EEG can show occipital paroxysmal discharges: long runs of repetitive, high amplitude, sharp and slow wave complexes, usually bilaterally. During seizures a remission of the occipital paroxysms can occur as also the appearance of occipital sharp waves, and then theta activity. A characteristic feature is occipital paroxysmal activity as long as the eyes are closed, but its disappearance or attenuation when they are open; a fixation-off sensitivity. Intermittent photosensitivity can also inhibit these paroxysms, but at a later stage as they are declining they may be provoked. The peak age of onset is from four to five years.

Late-Onset Childhood Idiopathic Occipital Epilepsy (LOE) is a rare manifestation of a type of childhood susceptibility syndrome, comprising of brief and diurnal seizures consisting of visual hallucinations, small multicoloured circular patterns, starting in the peripheral visual fields, becoming larger and spreading across the field, blindness or both. More complex hallucinations are rare, as is progression to convulsions. The mean age of onset is around eight years. Early onset seizures last longer, are infrequent and often nocturnal; they usually cease within a year and the prognosis is good. Conversely, those of late onset are short, mainly diurnal, last over several years and the prognosis is uncertain.<sup>10</sup>

As is well recognised in Idiopathic Photosensitive Occipital Seizures (IPOS), the seizures are most frequently precipitated by television and computer screens. They may start with bright, colourful rings or spots in the periphery of the visual fields, to be followed sometimes by impaired or blurred vision and deviation of the head or eyes. Some patients experience epigastric discomfort, nausea and vomiting, and sharp pains in the head. Throbbing headaches after the attacks are common.<sup>6</sup>

Diagnostic problems tend to arise in the type of occipital seizures classified by Panayiotopoulos<sup>11</sup> as Idiopathic Occipital Epilepsy with Visual Hallucinations (IOEVH). In his study of 1,360 patients, 63 had occipital seizures and nine had definite Idiopathic Occipital Epilepsy with Visual Hallucinations (IOEVH). These hallucinations were the first and often the only symptom; they were multicoloured in six, monochromatic in two, dichromatic in one and their shapes included circles, spots, squares, triangles and rectangles, often in combinations. Their location was

unilateral in six, but could be central or undefined and they could move and spin, and were flashing in four. During attacks vision was obscured only in the area occupied by the hallucinations. They usually lasted under a minute, but sometimes up to 20 minutes. Three of the patients had rare episodes of blindness lasting a few minutes, and ipsilateral deviation of the head and eyes could occur, as well as illusions of eye movements, eyelid fluttering and repetitive eyelid closure, sometimes progressing to generalised convulsions.

The question that has to be asked is whether these attacks are due to epilepsy or migraine. The patient's description of the visual aura should help in their differentiation. Typically, the epileptic elementary hallucinations are mainly coloured with circular patterns, are usually of short duration, and their individual components may multiply or move together to the contralateral side. Blindness is commonly associated with postictal headaches which are similar to migraine. In contrast, the visual auras of migraine usually start with flickering, black and white, linear and zigzag patterns in the centre of the visual field, gradually expanding over minutes towards the periphery of one hemifield, and frequently leaving a scotoma in their wake. Convulsions can rarely complicate an attack of migraine. So it has to be admitted that an overlap between the two conditions does occur.<sup>11</sup>

The diagnostic difficulties are well illustrated by a patient reported by Linder *et al.*<sup>14</sup> displaying a history of migraine with a visual aura, but with no history of epileptic seizures. An EEG taken during the visual aura showed spikes and spike-wave potentials, the findings on MRI during an attack were compatible with hyperaemia of the meningeal vessels. Treatment with anti-epileptic drugs was effective (but both conditions may respond to these). However, the patient complained of complex visual auras which were brightly coloured – a sign which is in favour of the diagnosis of epilepsy (Table 3).

#### BASILAR ARTERY MIGRAINE.

Basilar artery migraine should be considered as a distinct variant. Its main clinical features arise from disturbances of structures in the territory of the posterior cerebral arteries, and include cranial nerve, cerebellar, cochleovestibular, and corticobulbar symptoms and signs. Visual symptoms occur at the start of the attacks and consist of impaired vision and visual hallucinations which may last up to 30 minutes, and consciousness may be affected.<sup>2</sup> The associated headaches are often occipital. The EEG may show epileptic activity to confuse the diagnosis as there is nothing specific in the occurrence of occipital spike and wave discharges. They may occur in children with both idiopathic, especially absence seizures, and symptomatic epilepsy, and among those

with no evidence of fits.<sup>15</sup> A similar benign syndrome affects adolescents: seizures are rare and often follow a visual aura, and the EEG can show almost continuous epileptic activity in the occipitotemporal areas. Camfield *et al.*<sup>16</sup> report such patients, and consider that the ischaemic changes caused by the migrainous aura cause the EEG abnormalities.

COMMON FACTORS BETWEEN OCCIPITAL EPILEPSY AND MIGRAINE

Some people suffer from seizures undoubtedly of an epileptic nature, and never suffer from migraine type headaches; others complain of typical migraine and have never had a seizure. A few others for some reason or other have both<sup>17</sup> and the possibility has to be considered that there may well be a common factor in their aetiology, even if this is only a susceptibility to both.

A relationship exists between Benign Childhood Epilepsy with Occipital Paroxysms (BCEOP) and Benign Childhood Epilepsy with Centrottemporal Spikes (BCECTS),<sup>3</sup> and with idiopathic epilepsy with spike and wave discharges;<sup>2</sup> but the basis for this relationship is unclear. This is also true for epilepsy and migraine and over the years many papers have suggested a common cause for these two conditions. From this literature a few points will be raised. Both these conditions involve changes in the cerebral cortex. One intriguing, possible common factor is the spreading depression of Leão who, during studies to explain the electrocorticogram in experimental epilepsy, found that weak faradic or mechanical stimulation of the exposed cortex of rabbits caused a marked and enduring reduction of spontaneous electrical activity of the cortex which spread smoothly over the cortex and was due to biochemical changes.<sup>18</sup> A discharge, typical of experimental epilepsy may occur in a region of the cortex when it is reached by a wave of depression, the depression of cortical activity and the epileptic discharges appear to be closely related, and probably involve the same cortical structures. A wave of marked vasodilatation of the pial vessels and increased blood flow has been found to travel over the cortex simultaneously with the wave of depression elicited in rabbits by weak electrical or mechanical stimulation.<sup>19</sup> Cao *et al.*<sup>20</sup> postulated that the spreading depression of Leão was initially accompanied by transient

hypoperfusion which may be associated with the initiation of a migraine attack, whether or not there is a visual aura, the subsequent vasodilatation may induce the headache. If there are links, the initiator of spreading depression could be the reduced blood flow related to a disturbance of the autonomic nervous system, and that migraine headaches and epileptic seizures are a result of subsequent vascular changes.<sup>21</sup>

CONCLUSIONS

The more that is known about the variations between seizures arising in the occipital areas the more likely it is for their aetiology to be unravelled. Definitions of different epileptic syndromes are necessary if more is to be deduced about their genetic implications, prognosis and treatment. More research is required on the relative incidence of the various syndromes, and of the association of occipital epilepsy and migraine. Often, other members of the same family suffer from similar seizures and headaches but more needs to be known about the exact mode of inheritance. In this paper only benign idiopathic occipital lobe epilepsy is considered and not symptomatic occipital lobe epilepsy, although in fact the clinical manifestations may not significantly differ between the two.<sup>15</sup> The latter may be due to such causes as cerebral tumours, vascular lesions and trauma, and if suspicions are raised by additional symptoms and signs complex investigations may be needed.

The headaches of migraine, and the seizures and abnormal EEG discharges of epilepsy, are symptoms and signs of disorders of cerebral function. In most cases migraine and epilepsy appear to have different pathophysiological mechanisms in spite of certain overlaps. Until this inter-relationship is more clearly defined, they should be regarded as distinct clinical entities.

Andermann and Zifkin<sup>2</sup> suggest that classification of both conditions at a molecular level will eventually clarify these issues. Investigations with techniques such as positron emission tomography may help to elucidate the mechanisms which cause the symptoms, and whether they are the same or different in the different varieties. Ogunyemi and Adams,<sup>22</sup> using CAT and MRI scans, have shown that migraine-like symptoms following occipital lobe seizures may share similar pathophysiological disturbances, possibly related to serotonin mechanisms. The usefulness of classification into so many different syndromes may be less evident in a

TABLE 3  
Features helpful in diagnosis

	Age of onset	Clinical features	Drugs	Prognosis
<b>EBOS</b>	1–12 yrs	Ictal vomiting, deviation of eyes, impaired consciousness, hemiconvulsions, autonomic and behavioural disturbances, nocturnal onset, last 30 min, headache and visual hallucinations rare	Carbamazepine	Good
<b>LOE</b>	3–16 yrs	Visual hallucinations, blindness, deviation of eyes, loss of to uncertain consciousness, convulsions, post-ictal headaches, diurnal; last up to three min	Carbamazepine	Good to uncertain
<b>IPOS</b>	5–17 yrs	Visual hallucinations, blindness, deviation of eyes, vomiting, uncertain headache; last up to two hrs	Sodium valproate	Good to uncertain

busy clinic, and a cause of some confusion, until the facts are more clear-cut.

## REFERENCES

- <sup>1</sup> Martinez J-VL, Speciali JG. Migraine with visual aura versus occipital epilepsy. *Headache* 1997; **37**:113.
- <sup>2</sup> Andermann F, Zifkin B. The benign occipital epilepsies of childhood: an overview of the idiopathic syndromes and the relationship to migraine. *Epilepsia* 1998; **39(Suppl 4)**: S9-23.
- <sup>3</sup> Panayiotopoulos CP. Benign childhood epilepsy with occipital paroxysms: a 15-year prospective study. *Ann Neurol* 1989; **26**: 51-6.
- <sup>4</sup> Panayiotopoulos CP. Elementary visual hallucinations in migraine and epilepsy. *J Neurol Neurosurg Psychiat* 1994; **57**:1371-4.
- <sup>5</sup> Maher J, Ronen GM, Ogunyemi AO *et al*. Occipital paroxysmal discharges suppressed by eye opening: variability in clinical and seizure manifestations in childhood. *Epilepsia* 1995; **36**:52-7.
- <sup>6</sup> Guerrini R, Dravet C, Genton P *et al*. Idiopathic photosensitive occipital lobe epilepsy. *Epilepsia* 1995; **36**:883-91.
- <sup>7</sup> Ferrie CD, Beaumanoir A, Guerrini R *et al*. Early-onset benign occipital seizure syndrome. *Epilepsia* 1997; **38**:285-93.
- <sup>8</sup> Van den Hout BM, Van der Meij W, Wieneke GH *et al*. Seizure semiology of occipital lobe epilepsy in children. *Epilepsia* 1997; **38**:1188-91.
- <sup>9</sup> Panayiotopoulos CP. Benign childhood occipital seizures. *Arch Dis Child* 1998; **78**:3-4.
- <sup>10</sup> Panayiotopoulos CP. Early-onset benign childhood occipital seizure susceptibility syndrome: a syndrome to recognize. *Epilepsia* 1999; **40**:621-30.
- <sup>11</sup> Panayiotopoulos CP. Elementary visual hallucinations, blindness and headache in idiopathic occipital epilepsy: differentiation from migraine. *J Neurol Neurosurg Psychiat* 1999; **66**:536-40.
- <sup>12</sup> Oguni H, Hayashi K, Imai K *et al*. Study on the early-onset variant of benign childhood epilepsy with occipital paroxysms otherwise described as early onset benign occipital seizure susceptibility syndrome. *Epilepsia* 1999; **40**:1020-30.
- <sup>13</sup> Oguni H, Hayashi K, Imai K *et al*. Study on the early-onset benign occipital seizure susceptibility syndrome. *Brain Dev* 1999; **21**:504-5.
- <sup>14</sup> Linder A, Reiners K, Toyka KV. Meningeal hypoperfusion visualized by MRI in a patient with visual hallucinations and migraine. *Headache* 1995; **36**:53-7.
- <sup>15</sup> Talwar D, Rask CA, Torres F. Clinical manifestations in children with occipital spike-wave paroxysms. *Epilepsia* 1992; **33**:667-4.
- <sup>16</sup> Camfield PR, Metrakos K, Andermann F. Basilar migraine, seizures, and severe epileptiform EEG abnormalities. *Neurology* 1978; **28**:584-8.
- <sup>17</sup> Basser LS. The relation of migraine and epilepsy. *Brain* 1969; **92**:285-300.
- <sup>18</sup> Leão AAP. Pial circulation and spreading depression of activity in the cerebral cortex. *J Neurophysiol* 1944; **7**:391-6.
- <sup>19</sup> Leão AAP. Spreading depression of activity in the cerebral cortex. *Journal of Neurophysiology* 1994; **7**:358-90.
- <sup>20</sup> Cao Y, Welch KMA, Aurora S *et al*. Functional MRI-BOLD of visually triggered headache in patients with migraine. *Arch Neurol* 1999; **56**:548-4.
- <sup>21</sup> Gordon N. Migraine, epilepsy, post-traumatic syndromes, and spreading depression. *Develop Med Child Neurol* 1989; **31**:682-9.
- <sup>22</sup> Ogunyemi A, Adams D. Migraine-like symptoms triggered by occipital lobe seizures: response to sumatriptan. *Canad J Neurol Sci* 1998; **25**:151-3.