

IMAGES IN MEDICINE.

INTRAMURAL CORONARY ARTERY HAEMATOMA AS A CAUSE OF ACUTE CORONARY OCCLUSION DURING ANGIOGRAPHY

M.K. MacLennan, D.E. Newby and N.G. Uren, Department of Cardiology, Royal Infirmary, Edinburgh

CASE REPORT

A fifty-year-old male presented for elective coronary angiography. His first referral had been four months previously with a new history of central chest discomfort over a six-month period. He acquired relief from a GTN spray and had a long-standing history of gastro-oesophageal reflux disease. He was a Type 2 diabetic with a 12-month history of hypertension and 20 cigarette/day smoking habit. His medication included metformin 2 g daily, omeprazole 20 mg daily, perindopril 8 mg daily, fenofibrate 200 mg daily and aspirin. His father had a fatal myocardial infarction at 56 and his mother had a non-fatal myocardial infarction in her late fifties. His physical examination was normal with a blood pressure of 140/80. His resting 12 lead ECG was within normal limits. He performed three minutes of the Bruce protocol and developed over 1.5 mm ST segment depression in leads V4-6 at a heart rate of 100 bpm, associated with central chest discomfort. Bisoprolol 5 mg was added to his medication. His total cholesterol was 5.0 mmol/l with an LDL-cholesterol of 2.9 mmol/l and an HDL-cholesterol of 0.7 mmol/l.

Coronary angiography was performed using the Judkins technique. Left ventricular function was normal. Left coronary arteriography confirmed a proximal 80% diameter stenosis with a 95% mid-vessel lesion in the left anterior descending artery (LAD). His circumflex artery was normal with extensive collaterals to the right coronary artery. The right coronary artery was occluded proximally. After discussing these findings with the patient, a decision was made to proceed to percutaneous coronary intervention

of the LAD lesions. Following guide catheter insertion to left main stem, a hydrophilic 0.014 inch guide-wire was passed into the distal LAD without difficulty. Both lesions were balloon-dilated using a 3.0 x 20 mm angioplasty balloon catheter. The mid-vessel lesion was successfully stented deploying a 3.0 x 8 mm BX Velocity™ stent (Cordis) to 12 atmospheres. The proximal lesion was then stented with a 4.5 x 18 mm BX Velocity™ stent (Cordis) deployed to 14 atmospheres. A residual lesion was noted between the two deployed stents. This lesion was balloon-dilated using a 3.0 x 20 mm balloon catheter. At this point, the LAD became occluded in the mid-vessel with associated chest pain and ST segment elevation. A bolus injection of abciximab (Reopro™: a glycoprotein IIb/IIIa receptor antagonist) and intravenous opiate was administered to the patient immediately. The 3.0 x 20 mm balloon was inflated distal to the more distal stent thus providing a restoration of normal coronary blood flow with a residual intermediate lesion and a resolution of chest pain and ECG changes.

Once decided upon, intravascular ultrasound (IVUS) examination of the LAD was performed to identify the exact cause of the acute occlusion. On the pre-existing guide-wire, a 2.6 F 30 MHz Ultracross IVUS catheter (Boston Scientific Inc.) was passed into the distal vessel after a 300 µg intracoronary GTN bolus. An automated pullback at 0.5 mm/s was performed. This examination confirmed the presence of well-expanded stents, which were not overlapping (Figure 1). There was no evidence of intraluminal thrombus. However, a subintimal dissection was noted between the two stents, which had led the

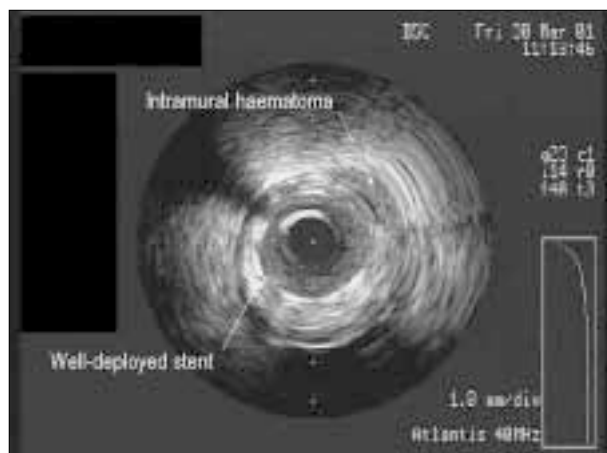


FIGURE 1

IVUS image demonstrating a well-deployed concentric stent with no intraluminal thrombus. An echo-lucent area is seen outside the stent margins at 2 o'clock. This represents the propagating intramural haematoma. The central back circle indicates the catheter blank and markers 1 mm apart.

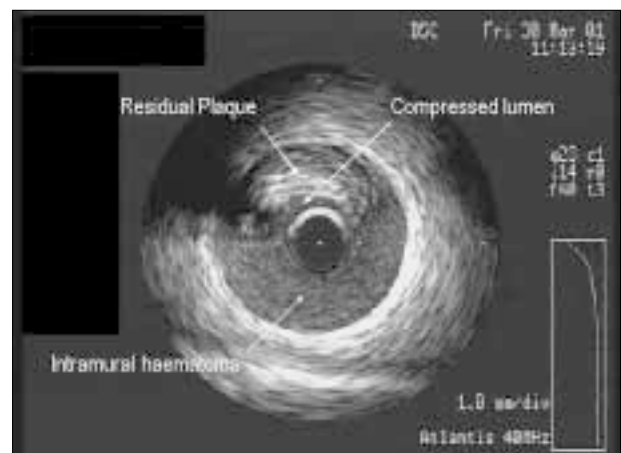


FIGURE 2

IVUS image demonstrating significant luminal compromise due to compression by haematoma (the crescentic shape from 2-9 o'clock). The moderately echo-lucent appearance, indicating high red blood cell velocity, suggests high blood flow within the haematoma.

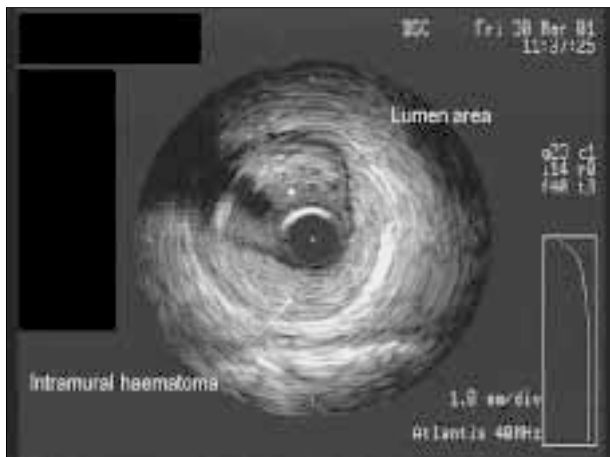


FIGURE 3

IVUS image demonstrating an improvement in lumen compromise. The echo-dense appearance, representing red blood cell stasis, demonstrates that the anterograde flow in the haematoma has in effect stopped.

formation of an intramural haematoma with active blood flow. It extended from this point between the stents to outside the second stent into the mid-vessel, which was stenosing, the coronary lumen over a length of 25 mm through extrinsic compression (Figure 2). A 4.0 x 13 mm BX Velocity™ stent (Cordis) was deployed between the two existing stents to cover the subintimal dissection and, thus, the entry point of the intramural haematoma. Repeat

IVUS examination confirmed an excellent result with the slowing of flow in the intramural haematoma and a residual coronary lesion of around 40% diameter stenosis (Figure 3). This mid/distal area was not balloon-dilated further.

The patient received a 12-hour infusion of abciximab. He made an uneventful recovery from the procedure and was discharged after 24 hours. Repeat coronary angiography two months later confirmed a focal 50% stenosis just distal to distal stent, which was successfully balloon-dilated. The patient remains well at follow-up.

COMMENTS

This case exhibits the value of intravascular ultrasound during coronary intervention. At the time of acute occlusion, it was uncertain if there was dissection and intra-luminal thrombus between the stents or distally. In order to devise the correct interventional approach in this acute setting, the IVUS demonstrated that although the vessel occlusion was occurring distal to the distal stent, the actual cause of this was dissection between the stents with a propagating intramural haematoma. This allowed the correct interventional approach, which was to cover the subintimal dissection between the stents, which then diminished active arterial flow into the haematoma. Consequent organisation and thrombosis of the haematoma was facilitated without distal lumen compromise. Further unguided balloon dilatation applied distally might have resulted in rupture of the haematoma in the mid/distal vessel leading to further complications.