

Nephrotic syndrome in a bee keeper: rediscovery of an extinct disease?

¹TF Hiemstra, ²KGC Smith, ³DV Hamilton

¹Research Fellow and Honorary Specialist Registrar; ²Genzyme Professor of Experimental Medicine, Cambridge Institute for Medical Research, Cambridge; ³Consultant Physician and Nephrologist, Jack Pryor Renal Unit, Norfolk and Norwich University Hospital, Norwich, UK

ABSTRACT An elderly beekeeper presented with nephrotic syndrome due to secondary amyloidosis. He developed progressive renal impairment and ultimately required dialysis. The patient had received multiple bee stings per day over seven decades without any allergic reactions. Here, we report secondary amyloidosis associated with recurrent bee venom exposure.

KEYWORDS Bee sting, kidney, nephrotic, secondary amyloidosis, venom

DECLARATION OF INTERESTS No conflict of interests declared.

Published online January 2009

Correspondence to TF Hiemstra, Cambridge Institute for Medical Research, Wellcome Trust/MRC Building, Box 139, Addenbrookes Hospital, Cambridge CB2 0XY, UK

tel. +44 (0)1223 331756
e-mail tfh24@cam.ac.uk

CASE REPORT

A 78-year-old man presented with nephrotic syndrome in 2006. Blood investigations were non-contributory and a diagnostic renal biopsy was performed, revealing secondary amyloidosis (SA) (Figure 1). Other aspects of the patient's history and examination were unremarkable, and notable for the absence of known aetiologies for SA. The patient developed progressive renal impairment and remained nephrotic, and became oliguric and ultimately required haemodialysis. He later revealed his favoured pastime of beekeeping. He started practising this art at the age of 13, during the wartime Britain's 'Dig for Victory' initiative. For a teenager during the Second World War protective wear was difficult to obtain, leading to 20–30 stings daily over the summer months. He kept bees for the succeeding 67 years, continuing to sustain multiple stings daily, and only more recently began to wear protective clothing which did not include gloves (Figure 2).

We hypothesised that chronic exposure to bee venom through multiple stings induced SA. A radioallergosorbent test revealed elevated anti-bee venom IgG consistent with continued bee venom exposure, and an elevated anti-bee venom IgE of 188 Ku/L (normal range <107) consistent with hypersensitivity to bee venom.

DISCUSSION

Acute renal failure due to multiple bee stings is well documented.¹ It is commonly due to acute tubular necrosis, pigment nephropathy secondary to haemolysis or rhabdomyolysis, or possibly interstitial nephritis.^{2,3} Bee venom exposure may be associated with albuminuria,⁴ and acute onset of nephrotic syndrome after bee sting is well described.^{5–8} However, despite an extensive literature search, we could find no previous reference to bee venom-associated amyloidosis. Our patient pointed out a reference in an early beekeeper's manual describing as matter of fact a 'toxic effect on the kidneys' not

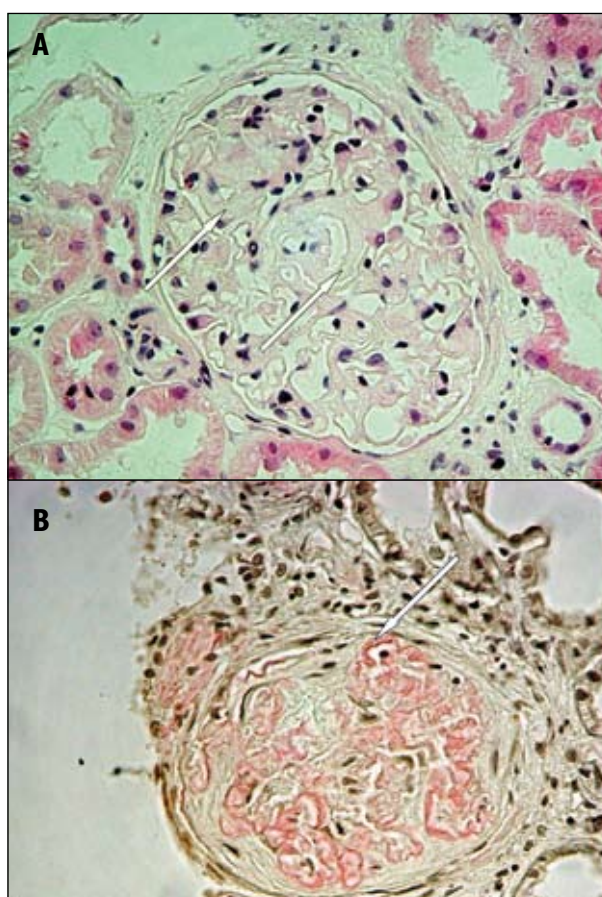


FIGURE 1 Renal biopsy from an elderly beekeeper presenting with a nephrotic syndrome due to secondary amyloidosis which progressed to renal impairment, ultimately requiring dialysis. (A) Haematoxylin and eosin stain showing marked and uniform eosinophilic thickening of glomerular capillary walls (arrow). (B) Congo red stain demonstrating a glomerulus with some sclerosis and amyloid deposition in capillary walls (arrow). There was insufficient tissue to perform immunofluorescence.

infrequently occurring late in the career of apiarists chronically exposed to venom of the European honey bee (*Apis mellifera*).⁹

Secondary amyloidosis is a disorder characterised by the tissue deposition of fibrils composed of fragments of serum amyloid A protein (SAA), an acute phase reactant. Serum amyloid A is inducible by pro-inflammatory cytokines such as IL-1 and TNF α ,¹⁰ which are induced by bee venom.¹¹ Secondary amyloidosis may complicate a variety of chronic inflammatory disorders, most commonly rheumatoid arthritis, inflammatory bowel disease, ankylosing spondylitis, familial fever syndromes and malignancy.¹² Such chronic inflammatory conditions were not present in our patient. However, the primary components of bee venom (mellitin and phospholipase A2) may produce an inflammatory response^{11,13} which may be local or systemic, is sometimes delayed and can produce a serum sickness-like illness.¹⁴

Apiculture has been practised in Britain for millennia, with the earliest archaeological evidence in Western Europe dating from around 3000 BC. Beekeepers were frequently recorded in the *Domesday Book*. However, the development of protective wear is only a recent occurrence.¹⁵ For the unprotected apiarist, 30 stings daily is common¹⁶ and congruent with the reported exposure to bee venom in our patient. We postulate that such exposure may have induced a 'chronic' acute phase reaction, analogous to a chronic inflammatory disorder, and ultimately led to the development of SA.

The absence of previous reports from the literature is not surprising for three reasons. First, SA was only relatively recently described,¹⁷ and earlier authors would have been ignorant of its existence. Secondly, the use of protective gear was common in the West during the 20th century. Thirdly, bee colonies are becoming increasingly docile due to forced selection by apiarists.¹⁸

REFERENCES

- Vetter RS, Visscher PK, Camazine S. Mass envenomations by honey bees and wasps. *West J Med* 1999; 170(4):223–7.
- Grisotto LS, Mendes GE, Castro I et al. Mechanisms of bee venom-induced acute renal failure. *Toxicol* 2006; 48(1):44–54.
- Zhang R, Meleg-Smith S, Batuman V. Acute tubulointerstitial nephritis after wasp stings. *Am J Kidney Dis* 2001; 38(6):E33.
- Elming H, Solling K. Urine protein excretion after Hymenoptera sting. *Scand J Urol Nephrol* 1994; 28(1):13–5.
- Revai T, Harmos G. Simvastatin treatment in nephrotic syndrome associated with a bee sting. *J R Soc Med* 1999; 92(1):23–4.
- Kawasaki S, Kaneoka H, Miyahara Y et al. [Case of nephrotic syndrome caused by bee sting and followed by spontaneous remission]. *Nippon Naika Gakkai Zasshi* 1997; 86(1):143–5.
- Tasic V. Nephrotic syndrome in a child after a bee sting. *Pediatr Nephrol* 2000; 15(3–4):245–7.
- Olivero JJ, Ayus JC, Eknayan G. Nephrotic syndrome developing after bee stings. *South Med J* 1981; 74(1):82–3.
- Gregg AL. *The philosophy and practice of bee keeping*. Kent: Bee-craft; 1949.
- Thorn CF, Lu ZY, Whitehead AS. Regulation of the human acute phase serum amyloid A genes by tumour necrosis factor- α , interleukin-6 and glucocorticoids in hepatic and epithelial cell lines. *Scand J Immunol* 2004; 59(2):152–8.
- Stuhlmeier KM. Apis mellifera venom and melittin block neither NF-kappa B-p50-DNA interactions nor the activation of NF-kappa B, instead they activate the transcription of proinflammatory genes and the release of reactive oxygen intermediates. *J Immunol* 2007; 179(1):655–64.
- Dember LM. Amyloidosis-associated kidney disease. *J Am Soc Nephrol* 2006; 17(12):3458–71.
- Bomalaski JS, Ford T, Hudson AP et al. Phospholipase A2-activating protein induces the synthesis of IL-1 and TNF in human monocytes. *J Immunol* 1995; 154(8):4027–31.
- Reisman RE, Livingston A. Late-onset allergic reactions, including serum sickness, after insect stings. *J Allergy Clin Immunol* 1989; 84(3):331–7.
- Fraser HM. *Beekeeping in antiquity*. London: University of London; 1932.
- Wilson B. *The hive: the story of the honeybee and us*. London: Murray; 2004.
- Dahlin DC. Secondary amyloidosis. *Ann Intern Med* 1949; 31(1):105–19.
- Dews JE, Milner E, British Isles Bee Breeders' Association. *Breeding better bees using simple modern methods*. 3rd ed. Cogenhoe: British Isles Bee Breeders' Association; 2004.
- Butler C. *The feminine monarchy or the historie of bees shewing their admirable nature, and properties, their generation, and colonies, their government, loyaltie, art, industrie, enemies, warres, magnanimitie, &c.* London: Iohn Havilland for Roger Iackson; 1623.
- Visscher PK, Vetter RS, Camazine S. Removing bee stings. *Lancet* 1996; 348(9023):301–2.



FIGURE 2 A recent picture of the patient at work in his apiary, now wearing a protective face mask. Note the absence of gloves.

CONCLUSION

Although causality remains speculative, we propose chronic bee venom exposure as a novel cause of SA. We have advised our patient to avoid sustaining any further stings by the use of full protective wear. Nevertheless, where a sting is sustained, we have urged him to heed advice offered by Charles Butler in 1623: 'Instantly wipe off the bee, sting and all, and wash the place with your spittle.'¹⁹ While the therapeutic properties of 'spittle' remain to be proven, rapid removal of the sting has been shown to reduce envenomation.²⁰

Acknowledgements The authors wish to thank the patient for permitting access to both his apiary and library, and for his consent to and support of this paper.