

The challenging diagnosis of cardiac amyloidosis

¹A Gavin, ²CJ Coats, ³W Wallace, ⁴AD Flapan

¹Specialist Registrar in Cardiology; ²Senior House Officer in Cardiology; ³Consultant Pathologist; ⁴Consultant Cardiologist, Royal Infirmary of Edinburgh, Edinburgh, UK

ABSTRACT Cardiac amyloidosis is a rare condition. Early diagnosis allows for more effective treatment with subsequent improvements in patient quality of life and survival. There is, however, often a significant delay between the initial presentation with symptoms and the eventual diagnosis. We present seven individual cases presenting to our centre over a 12-month period for whom the final diagnosis was cardiac amyloidosis. We look at the difficulties encountered and alternative diagnoses that were considered before the eventual diagnosis of cardiac amyloidosis was made. We discuss the apparent discrepancies often encountered between the clinical signs and the results of various investigations. We review the various tests that can help the clinician to make the diagnosis in patients with suspected cardiac amyloidosis and look at the treatment options. Finally, we conclude that careful evaluation of the clinical status in the context of all available results should allow early diagnosis and treatment, thereby improving long-term prognosis.

Published online July 2008

Correspondence to A Gavin,
Department of Cardiology,
Royal Infirmary of Edinburgh,
51 Little France Crescent,
Edinburgh EH16 4SA, UK

tel. +44 (0)131 242 1910

fax. +44 (0)131 242 1914

e-mail andrew-gavin@hotmail.com

KEYWORDS Amyloid heart disease, amyloidosis, case series

DECLARATION OF INTERESTS No conflict of interests declared.

INTRODUCTION

Amyloidosis is a disease caused by the infiltration of various organs with insoluble eosinophilic protein fibrils. These extracellular amyloid proteins are composed of amino-acid chains arranged in a cross-beta pattern together with various sugars and other components such as serum amyloid P.¹ All these cross-beta type structures exhibit apple-green birefringence under the microscope when stained with Congo red and viewed under polarised light.

The first reported case of what came to be known as amyloid was published in 1639, when large white stones were discovered in the spleen of a young man at autopsy.² In 1828 John Abercrombie, physician to the king in Scotland, and his colleagues at the Edinburgh School were the first to describe the waxy appearance of the liver. The term 'amyloid' was coined in 1838 by the German botanist Matthias Schleiden to describe a normal amylaceous constituent in plants. It was adopted by the German pathologist Rudolf Virchow in 1860 to describe the pathological appearances in amyloidosis. Cardiac involvement, described as 'weakness of the heart muscle', has been recognised since the mid-1850s, while the association with myeloma was first recognised by Hermann Weber in 1867.³

Until fairly recently, amyloidosis was classified as primary (often associated with underlying plasma cell dyscrasia), senile, familial and secondary (usually associated with various connective tissue and inflammatory bowel diseases). However, amyloidosis is now classified

chemically, depending on the nature of the fibrillary protein.⁴ Twenty-three different fibrillary proteins have been described in human amyloidosis (Table 1).

Most cases of what previously was termed amyloid are associated with immunoglobulin light chain fibrillary proteins (AL amyloidosis). AL amyloidosis is a monoclonal plasma cell disorder closely related to multiple myeloma, and treatment mirrors the treatment of multiple myeloma. Similarly, those previously classified with 'senile' amyloid and many cases of familial amyloidosis are associated with the fibrils of transport protein transthyretin (TTR) and are now termed ATTR. Although familial amyloidosis rarely affects the heart, specific mutations in the transthyretin (ATTR) and apolipoprotein-AI (AApoAI) are associated with predominant cardiac involvement.

Reactive amyloidosis (AA amyloidosis) was formerly termed secondary amyloidosis and is the most common systemic amyloidosis worldwide. It is associated with chronic inflammation and occurs in various inflammatory, infective and neoplastic disorders. The precursor protein is a normal-sequence apo-SAA (serum amyloid A protein), which is an acute phase reactant that circulates bound to high-density lipoprotein.

In all forms of amyloidosis the cell secretes the precursor protein in a soluble form that becomes insoluble at some tissue site, compromising organ function. Many patients with amyloidosis have multi-system involvement at diagnosis. AL amyloidosis should be considered in any patient who presents with nephritic range proteinuria with or without renal insufficiency, non-dilated

cardiomyopathy, peripheral neuropathy, hepatomegaly or autonomic neuropathy. Initial investigation is aimed at confirming the diagnosis of amyloidosis by tissue biopsy with subsequent tests to establish the type and extent of the disease.

Biopsy of an affected organ is usually diagnostic, although less invasive alternatives, such as fat aspiration or rectal biopsy, should also be considered. Amyloid deposits classically produce red-green birefringence under polarised light when stained with Congo red.

Once the presence of amyloidosis has been confirmed, it is imperative that the amyloid type is established to plan appropriate treatment. Antibodies have been developed for most known amyloid proteins. Immunohistochemical staining of the biopsied tissue with a panel of amyloid protein antibodies is used to establish the nature of the underlying fibrillary protein. However, in AL amyloidosis results are often inconclusive due to background normal immunoglobulins. In situations where immunohistochemistry is inconclusive, DNA analysis or fibril protein sequencing can be used to obtain a definitive diagnosis.⁵ In cases of AL amyloidosis it is important to look for evidence of an underlying plasma cell dyscrasia, for example myeloma.

As well as the type of amyloidosis, it is imperative to establish the extent of organ involvement. Generalised abnormalities of liver function are rare, although an elevated alkaline phosphatase is commonly found. The chest X-ray may show reticulo-nodular shadowing in pulmonary amyloidosis, and there may be impaired CO diffusion on pulmonary function tests. Serum amyloid P (SAP) scintigraphy is routinely performed in most individuals referred for assessment and is useful in assessing the distribution of organ involvement as well as the response to treatment. However, SAP scintigraphy is unable to image amyloid in the moving heart,⁶ and electrocardiograms (ECG) and echocardiograms are essential. Nerve conduction studies may be required where neuropathy is the predominant symptom, and nerve biopsy is occasionally required to establish the diagnosis. Poor prognostic factors at presentation are echocardiographic evidence of cardiac involvement, a large amyloid load on SAP scintigraphy, autonomic neuropathy, hyperbilirubinaemia and associated myeloma.⁵

Cardiac amyloidosis is characterised by the infiltration of extracellular amyloid protein throughout the myocardium, valves and perivascular tissues.⁷ This may result in restrictive cardiomyopathy, coronary insufficiency producing chest pain or myocardial infarction,⁸ valvular dysfunction,⁹ atrial thrombus¹⁰ or cardiac arrhythmias.¹¹ ECG changes may include small voltage QRS complexes, first-degree heart block and non-specific ST segment changes. The degree of cardiac involvement varies with the type of amyloidosis. Senile amyloidosis (ATTR)

TABLE 1 Amyloidosis, associated fibrillary proteins and their clinical manifestations (reproduced from BA Baethge and DR Jacobson⁴ with permission from eMedicine)

Type	Fibril protein	Clinical setting
Systemic	Immunoglobulin light chains	Plasma cell dyscrasia
	Transthyretin	Familial amyloidosis, senile amyloidosis
	A amyloidosis	Inflammation-associated amyloidosis, familial Mediterranean fever
	β_2 -microglobulin	Dialysis-associated amyloidosis
	Immunoglobulin heavy chains	Systemic amyloidosis
Hereditary	Fibrinogen α chain	Familial systemic amyloidosis
	Apolipoprotein-AI	Familial systemic amyloidosis
	Apolipoprotein-AII	Familial systemic amyloidosis
	Lysozyme	Familial systemic amyloidosis
	β protein precursor	Alzheimer's syndrome, Down's syndrome, hereditary cerebral haemorrhage with amyloidosis
Central nervous system	Prion protein	Creutzfeldt-Jakob disease, Gerstmann-Sträussler-Scheinker disease, fatal familial insomnia
	Cystatin C	Hereditary cerebral haemorrhage with amyloidosis
	ABri precursor protein	Familial dementia (British)
	ADan protein	Familial dementia (Danish)
Ocular	Gelsolin	Familial amyloidosis (Finnish)
	Lactoferrin	Familial corneal amyloidosis
	Keratoepithelin	Familial corneal dystrophies
Localised	Calcitonin	Medullary thyroid carcinoma
	Amylin	Islet amyloid polypeptide amyloidosis
	Atrial natriuretic factor amyloidosis	Isolated atrial amyloidosis
	Prolactin	Pituitary amyloidosis
	Keratin	Cutaneous amyloidosis
	Medin	Aortic amyloidosis in elderly people

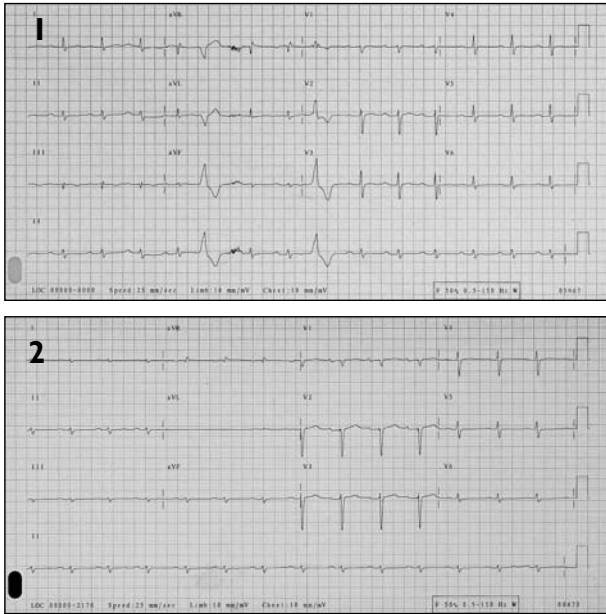


FIGURE 1 ECGs from Case 1, a 70-year-old man who presented with exertional dyspnoea, chest pain and a two-year history of joint pains, lethargy and weight loss. An initial ECG showed sinus rhythm with first-degree heart (1.1); a later ECG showed progression with a reduction in the QRS voltage in the limb leads with loss of the R wave in the anterior chest leads (1.2). A treadmill test was terminated early with widespread infero-lateral ST depression.

presents with almost exclusive cardiac involvement. Individuals with cardiac amyloidosis usually present with dyspnoea, a common and non-specific symptom, and early cardiac investigations are often unhelpful or misleading.

This case series looks at the clinical presentation of seven patients for whom the final diagnosis was cardiac amyloidosis. We discuss some of the diagnostic difficulties encountered that contributed to a delay in diagnosis.

Case 1

A 70-year-old man presented with exertional dyspnoea and chest pain. He gave a two-year history of joint pains, lethargy and weight loss. The initial ECG showed sinus rhythm with first-degree heart block (Figure 1.1). His echocardiogram and chest X-ray were reported as normal. He went on to have a treadmill test, which was terminated early with widespread inferolateral ST depression. A subsequent coronary angiogram demonstrated normal coronary arteries.

The patient's dyspnoea persisted, and he was therefore referred for a respiratory opinion. Pulmonary function tests revealed a mildly obstructive defect, and a repeat echocardiogram demonstrated a small pericardial effusion. No cause for his dyspnoea was identified, and he was referred for investigation of possible sleep apnoea.

A computerised tomography (CT) scan of the thorax, however, showed features of cardiac failure, which

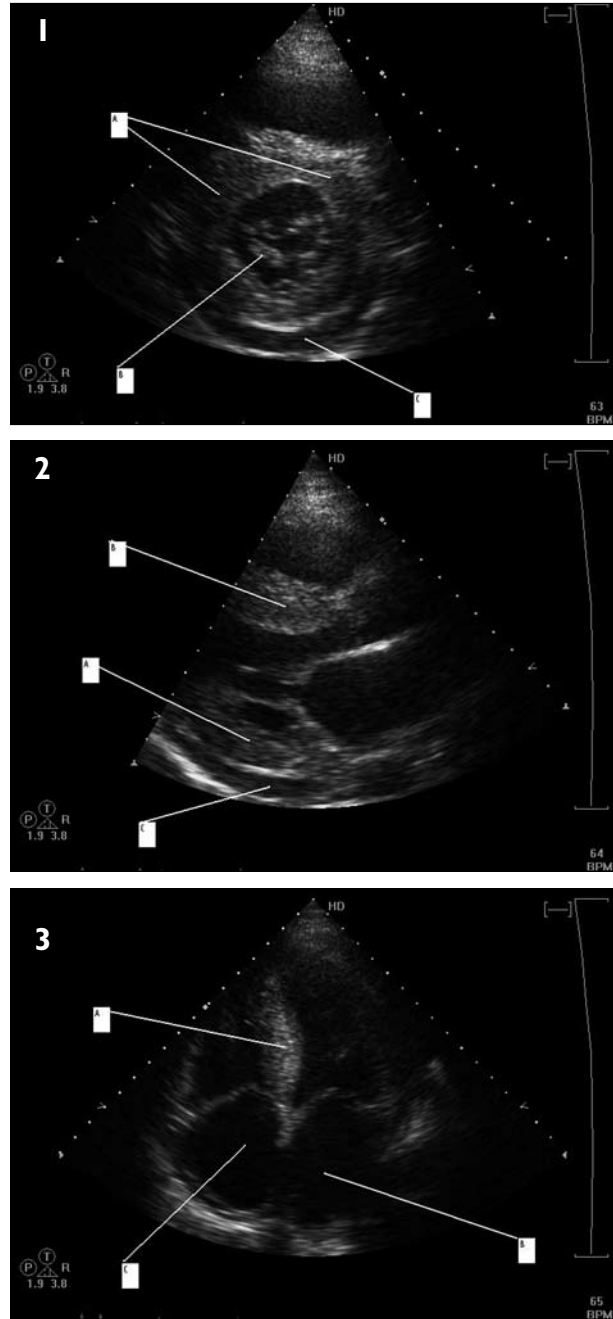


FIGURE 2 Echocardiogram suggestive of an infiltrative process from Case 1, whose CT scan at this stage showed features of cardiac failure. A coronary angiogram was normal. 1: Parasternal short axis view demonstrating a concentric thickened left ventricle (A) with thickening of the mitral valve leaflets (B). A small pericardial effusion is also demonstrated (C). 2: Parasternal long axis view demonstrating thickening of the left ventricular posterior wall (A) and septum (B) with the typical speckling appearance seen in cardiac amyloidosis. A pericardial effusion is again visualised (C). 3: A four-chamber view demonstrating marked hypertrophy of the inter-ventricular septum (A) with enlargement of the left (B) and right (C) atria.

prompted us to repeat the cardiac investigations. By this stage, the ECG changes had progressed with a reduction in the QRS voltage in the limb leads, with loss of the R wave in the anterior chest leads (Figure 1.2). The

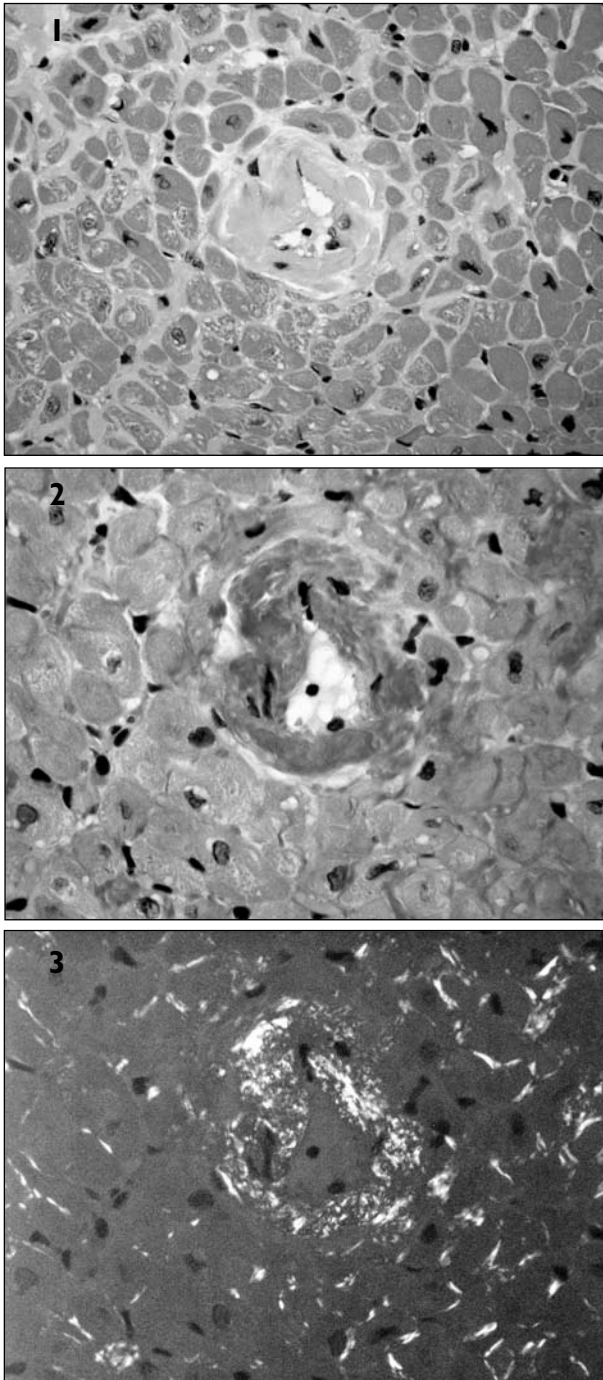


FIGURE 3 Photomicrographs of an endomyocardial biopsy from Case 1. (1) shows the deposition of amorphous eosinophilic material in the wall of a small intra-myocardial vessel with similar material identifiable around adjacent myocytes. Further sections stained with Congo red demonstrate this material to stain positively (2) and to show an apple-green birefringence pattern typical of amyloid when viewed by cross polarisation. Further characterisation of the type of amyloid present in the tissues can be carried out by immunohistochemistry using specific antibodies to the different types of amyloid proteins. 1: haematoxylin and eosin; 2 and 3: Congo red; original magnification $\times 400$.

echocardiogram now suggested an infiltrative process (Figure 2). The patient was admitted for cardiac and rectal biopsy, which provided immunohistochemical

confirmation of AL-type amyloidosis (Figure 3). He was later found to have an underlying lambda light chain secreting plasma cell dyscrasia with multiple lytic skull lesions. Bone marrow examination revealed $>10\%$ plasma cells. The patient was referred to a specialist centre for further management. He began chemotherapy but died of progressive cardiac failure two months after the diagnosis was made and 22 months after he first presented with symptoms of breathlessness.

Case 2

A 59-year-old woman presented to her GP with an 18-month history of worsening exertional dyspnoea. She smoked 20 cigarettes a day and consumed 50 units of alcohol per week. There was no history of chest pain, but she complained of ankle swelling and orthopnoea. Her chest X-ray showed an enlarged heart with mild pulmonary oedema, and a provisional diagnosis of alcohol-related cardiomyopathy was made.

At the cardiology outpatient review the patient was noted to have generalised bruising, a soreness in her mouth and numbness in her hands suggestive of bilateral carpal tunnel syndrome. The ECG showed sinus rhythm with small QRS complexes in the limb leads and Q waves across the anteroseptal leads. The echocardiogram showed a stiff left ventricle with mild left ventricular systolic impairment and severe left ventricular hypertrophy. Doppler filling showed a restrictive pattern. The initial suspicion was of cardiac amyloidosis, and admission was arranged for further investigation.

Rectal biopsy was performed. Congo red stain for amyloid confirmed apple-green birefringence around vessels in the lamina propria and muscularis mucosa consistent with systemic amyloidosis. Cardiac biopsy similarly confirmed the presence of amyloid within the myocardial fibres and deposited in the vessel walls. Immunoglobulins revealed an IgG lambda myeloma and lambda free light chain excess. The patient began chemotherapy, and her condition initially stabilised. However, she developed progressive cardiac failure and died 26 months after the initial diagnosis was made.

Case 3

A 76-year-old man was referred to cardiology outpatients with dyspnoea and exertional chest pain. There were no symptoms of cardiac failure. He had a history of hypertension and was taking bendroflumethiazide and aspirin. His ECG showed sinus rhythm with normal amplitude of the QRS complexes. The chest X-ray showed an enlarged heart with mild pulmonary oedema. His echocardiogram showed good left ventricular function and normal-sized chambers with moderate concentric left ventricular hypertrophy. He exercised for nine minutes before stopping due to breathlessness and inferior ST segment depression. He was diagnosed with angina and commenced on a long-acting nitrate. Eighteen

TABLE 2 Electrocardiogram features suggestive of cardiac amyloidosis

Small voltage QRS complexes
First-degree atrioventricular block
Q waves inferiorly
Pseudo-infarct pattern
Small or absent R waves in right precordial leads
Bundle branch block with abnormal axis deviation
Atrial fibrillation

TABLE 3 Echocardiographic features suggestive of cardiac amyloidosis

Left ventricular hypertrophy (in the presence of small voltage QRS complexes)
Right ventricular hypertrophy
Granular, sparkling appearance to the hypertrophied muscle
Small ventricular chamber size
Left ventricular diastolic impairment
Restrictive mitral inflow pattern on echocardiography (large E wave, small A wave with E:A ratio >2)
Systolic function often normal
Biatrial dilatation with thickening of the intra-atrial septum
Thickened valve leaflets
Pericardial effusion

months later he developed congestive cardiac failure, and a further echocardiogram suggested cardiac amyloidosis. His clinical condition deteriorated before a tissue diagnosis could be made. Post-mortem examination confirmed the presence of amorphous eosinophilic material disrupting the cardiac muscle fibres. These showed apple-green birefringence under polarised light, confirming the diagnosis of cardiac amyloidosis.

Case 4

A 53-year-old woman was referred to general medicine outpatients with a 12-month history of exertional chest pain. Her initial ECG showed inferior ST segment flattening, which worsened during exercise testing in association with chest tightness. Coronary arteriography showed normal coronaries. She was reassured and discharged from follow-up.

Two years later the woman was re-referred with exertional chest pain and dyspnoea. Her ECG at this stage was very abnormal, with left axis deviation and widespread lateral ST depression. The echocardiogram showed moderate left ventricular systolic impairment with asymmetric left ventricular hypertrophy. A provisional diagnosis of hypertrophic cardiomyopathy was made. Cardiac magnetic resonance imaging (MRI) showed gross free wall and septal hypertrophy, with obliteration of the left ventricle cavity in systole.

The patient's symptoms progressed over the next three months – she reported weight loss, constipation and general lethargy and developed pleural effusions. Her ECG by now showed low voltage complexes in comparison with previous recordings, with a pseudo-infarct pattern in her anterior leads. Further tests revealed an abnormal liver function and an IgG lambda paraprotein band. However, rectal biopsy was negative for amyloid. Bone marrow examination showed a plasma cell population and cardiac biopsy later demonstrated AL amyloidosis.

She was referred to the National Amyloidosis Centre in London but died from progressive cardiac failure before commencing chemotherapy, only six weeks after diagnosis.

Case 5

A 70-year-old woman presented with exertional chest pain and wheeze. Her ECG showed first-degree heart block and incomplete left bundle branch block. Blood tests and chest X-ray were normal. A treadmill test was terminated after 2½ minutes due to dyspnoea and slight ST depression in her inferior leads. Pulmonary function tests showed normal lung volumes with evidence of moderate airflow obstruction. The airflow obstruction was shown to improve with inhaled salbutamol. Her echocardiogram showed good left ventricular systolic function with asymmetrical hypertrophy at the interventricular septum. She was treated with inhalers for late-onset asthma.

Two years later the patient presented with atrial fibrillation. This was associated with a fast ventricular rate. Her echocardiogram again showed normal systolic function. Over the next six months her symptoms progressed with worsening dyspnoea, exertional chest pain and reduced exercise tolerance. She had further admissions with pulmonary oedema and repeated echocardiograms, all demonstrating left ventricular hypertrophy and good systolic function – out of keeping with her clinical symptoms. A thallium scan showed homogenous myocardial perfusion.

The patient was referred to our tertiary centre for further investigation. Her echocardiogram showed left ventricular hypertrophy with good systolic function, biatrial enlargement and mild mitral regurgitation. An initial diagnosis of hypertrophic cardiomyopathy was made. Symptoms progressed quickly over several months: she complained of weight loss, poor appetite and constipation. At this stage there was visible macroglossia and periorbital oedema (both strongly suggestive of AL amyloidosis) as well as parotid gland enlargement. Kussmaul's sign (a rise in the jugular venous pressure on inspiration) was positive, indicating a probable restrictive cardiomyopathy. Rectal biopsies confirmed AL amyloidosis.

The patient was referred to the National Amyloidosis Centre for assessment. After discussion she opted for treatment with a combination of oral thalidomide and

TABLE 4 Comparison of presenting features, diagnosis and investigations of seven patients

Feature	Patient 1	Patient 2	Patient 3	Patient 4	Patient 5	Patient 6	Patient 7
Presenting symptoms	SOBOE, exertional CP	SOBOE, CCF, bruising, neurological symptoms	SOB at rest, exertional CP	Exertional chest pain	Exertional chest pain, dyspnoea	Lower limb weakness, breathlessness, fatigue, presyncope	Dyspnoea, dizziness
ECG	Sinus rhythm, small complexes (3 mm), left axis deviation, inferolateral T-wave flattening	Sinus rhythm, peaked T waves, small complexes (4 mm) in limb leads, anteroseptal limb leads	Sinus rhythm, generalised ST segment flattening, normal sized QRS complexes	SR inf ST flattening	First-degree heart block, left axis deviation	Trifascicular block	SR, small inferior complexes (3 mm), poor R-wave progression
ETT	Inferolateral ST depression at 5 minutes	Not performed	9 min inf ST depression	Inferolateral ST segment depression	Minor inferior ST depression at 2 min 30 sec	Not performed	Not performed
Initial echo	Normal	Severe left ventricular hypertrophy, mildly impaired systolic function, restrictive mitral inflow pattern	Moderate concentric LVH, good systolic function	Asymmetrical septal hypertrophy, moderately impaired systolic function	Asymmetrical septal hypertrophy, good systolic function	Moderate systolic dysfunction, restrictive mitral inflow pattern	Left ventricular hypertrophy, normal systolic function
Initial diagnosis	Angina, asthma	Alcoholic cardiomyopathy	Angina	Angina, hypertrophic cardiomyopathy	Late-onset asthma	Motor neurone disease	Hypertensive heart disease
Time to diagnosis	17 months	12 months	18 months	27 months	32 months	12 months	6 months
CXR	Cardiomegally, bilateral pleural effusions	Cardiomegally	Cardiomegally, pulmonary oedema	Cardiomegally	Normal	Cardiomegally	Cardiomegally
Underlying cause	Myeloma, AL amyloidosis	Myeloma, AL amyloidosis	Amyloidosis (post-mortem diagnosis)	Myeloma, AL amyloidosis	AL amyloidosis, lambda secreting plasma cell dyscrasia	ATTR amyloidosis	Amyloidosis (post-mortem diagnosis)
Serum creatinine (at diagnosis, $\mu\text{mol/l}$)	114	118	132	107	114	70	182
Urinary protein loss	0.86 g (0.43 g/24 hour of lambda Bence Jones protein)	Not performed	Not performed	1.55 g	0.18 g (0.11 g lambda light chains)	0.18 g	Not performed
NT-proBNP	2,221 pmol/L	1,022 pmol/L	Not performed	550 pmol/L	Not performed	Not performed	Not performed
Serum alkaline phosphatase (at diagnosis, U/L)	151	112	107	105	83	66	198

cyclo-phosphamide. She initially appeared to progress well but subsequently developed progressive cardiac failure and died 14 months following diagnosis.

Case 6

A 70-year-old man presented with a 12-month history of progressive dyspnoea, fatigue and presyncopal episodes, six years after coronary bypass grafting. He had been investigated by his GP for weight loss and anaemia and had subsequently been referred to neurology with lower limb weakness. An initial diagnosis of motor neurone disease was made.

However, the patient's lower limb weakness progressed with bilateral sensory loss and generalised hyporeflexia more in keeping with a systemic illness. He was referred to cardiology outpatients because of orthostatic hypotension and cardiac failure. His ECG showed sinus rhythm with first-degree atrioventricular (AV) block, left axis deviation and right bundle branch block. His echocardiogram demonstrated moderate generalised systolic dysfunction with a thick, echo-dense interatrial septum. The left atrium was enlarged with moderate mitral regurgitation, and tissue velocity imaging confirmed a restrictive pattern. The combination of autonomic symptoms and a restrictive cardiomyopathy raised the suspicion of amyloidosis. There were no paraprotein bands on plasma electrophoresis. A bone marrow trephine revealed an excess of plasma cells of uncertain significance. Amyloid deposits were confirmed on both rectal and cardiac biopsy. Subsequent immunohistochemistry confirmed systemic transthyretin-related amyloidosis. Although frail and cachectic at the time of presentation, the patient responded well to chemotherapy and his condition remained stable 22 months after the initial presentation.

Case 7

A 66-year-old woman presented acutely with progressive dyspnoea and dizziness. Her chest X-ray showed cardiomegaly and pulmonary oedema. Her ECG showed small inferior complexes with poor R-wave progression anteriorly. Cardiac enzymes were within normal limits. The echocardiogram showed left ventricular hypertrophy but normal systolic function. A diagnosis of hypertensive heart disease was made, and her transient left ventricular dysfunction was attributed to poor blood pressure control.

Six months later the patient returned with worsening dyspnoea. She was unable to carry out an exercise test and went forward for coronary arteriography, which was normal. Her dyspnoea progressed with the development of pleural effusions. Her ECG remained unchanged, with small voltage complexes. The repeat echocardiogram showed concentric left ventricular hypertrophy (LVH) with moderately impaired systolic function and moderate mitral and tricuspid regurgitation. Her liver function was

also now deranged. After further cardiology review, a clinical diagnosis of amyloidosis was considered in view of macroglossia and signs of restrictive cardiomyopathy. Her condition deteriorated and she died from multi-organ failure before a tissue diagnosis could be made. Post-mortem examination confirmed widespread AL amyloid disease.

DISCUSSION

This case series illustrates the various presentations of cardiac amyloidosis. The diagnosis of a multi-system disease is not easy; however, in retrospect the clinical clues are often present at an early stage. Interpretation of basic cardiac investigations should be performed in the context of a thorough history and careful clinical examination. The presence of advanced heart failure without any clearly identifiable pathology should alert the suspicious clinician, and discrepancies between investigations and clinical signs should provide an early warning.

The management of cardiac amyloidosis is two-fold, involving treatment of heart failure alongside treatment of the underlying amyloid process. Diuretic treatment is the mainstay of heart failure treatment. Angiotensin-converting enzyme (ACE) inhibitors are poorly tolerated because of symptomatic hypotension.¹² Digoxin is bound to amyloid fibrils resulting in increased susceptibility to drug toxicity.^{13,14} There have been reports of an increased incidence of sudden death in patients with cardiac amyloidosis treated with digoxin.¹⁵ Calcium channel blockers are also bound to amyloid fibrils and have been shown to worsen clinical heart failure in cardiac amyloidosis.¹⁶ Many individuals have highly symptomatic orthostatic hypotension for which α blockade with midodrine may be beneficial.¹⁷

Treatment of the underlying amyloid process depends on the type of amyloidosis and requires unequivocal amyloid typing. This has been improved by the recent introduction of assays for the circulating amyloid precursor proteins SAA in AA amyloidosis and serum immunoglobulin free light chains in AL amyloidosis.

By targeting the clonal plasma cells producing the monoclonal immunoglobulin light chains with chemotherapy agents, amyloid formation can be halted, organ function is preserved and survival is improved in AL amyloidosis.^{18,19} Sensitive immunoassays for AL fibril precursor protein allow us to monitor an individual's response to chemotherapy and tailor a regime appropriately. A sustained reduction in the concentration of aberrant monoclonal light chains by 50% is associated with improved survival.¹⁹ High-dose chemotherapy with peripheral autologous stem cell rescue has become increasingly popular but has a high treatment-associated mortality.¹⁸ However, many individuals with AL amyloidosis tolerate this aggressive chemotherapy poorly, and the presence of cardiac amyloidosis is associated with increased mortality

and morbidity from peripheral stem cell transplantation.^{20,21} Those intolerant of high-dose chemotherapy may respond to intermediate-dose chemotherapy with vincristine, adriamycin and dexamethasone or melphalan and dexamethasone. Oral melphalan and prednisolone are better tolerated than more aggressive regimens, but many patients fail to respond.²²

The treatment of the underlying inflammatory condition in AA amyloidosis that reduces the SAA concentration leads to improved survival.²³ New agents that inhibit tumour necrosis factor and interleukin 1 suppress the acute phase response in many inflammatory conditions.²⁴ In familial Mediterranean fever, colchicine largely prevents the development of AA amyloidosis. Eprodisate, a new class of agent that inhibits the polymerisation of amyloid fibrils and deposition of fibrils in the tissues, has recently shown promising results in slowing the decline in renal function in AA amyloidosis.²⁵

Cardiac transplantation for cardiac amyloidosis is rarely performed because of concerns of amyloid deposition in the transplanted heart. Recently, sequential heart and stem cell transplants in young patients without renal, gastrointestinal or autonomic involvement have shown some promise.^{26,27}

By reviewing patient records we have highlighted particular features in the history, examination and subsequent investigation that should prompt the clinician to consider the possibility of cardiac amyloidosis in patients with unexplained cardiac symptoms. In all of these cases progressive exertional dyspnoea was the main presenting symptom. Four patients gave a history of exertional chest pain – although not always typical of angina. Non-cardiac symptoms (Case 6) should also suggest the presence of a multi-system disease. Weight loss and lethargy (Case 1) are non-specific, but in the elderly patient should raise the possibility of myeloma, particularly in the context of anaemia. Weight loss is also a common feature of AL amyloidosis in the absence of underlying myeloma. Orthostatic hypotension and constipation suggest autonomic involvement; abdominal discomfort may suggest organomegaly. Periorbital purpura and macroglossia are frequently observed in systemic AL amyloidosis.

The characteristic signs of a restrictive cardiomyopathy are not easy to elicit. The jugular venous pressure (JVP) may be elevated and Kussmaul's sign (JVP that rises paradoxically with inspiration) detected. The apex is usually palpable and undisplaced. Heart sounds may be distant with an audible S3 and S4. The restricted ventricular filling may result in peripheral oedema, ascites and hepatomegaly. Extra-cardiac manifestations are suggestive of a systemic illness. The presence of bruising, specifically periorbital purpura, and an enlarged tongue are pathognomonic of systemic amyloidosis (Case 2).

ECG

Although there are no diagnostic ECG findings in cardiac amyloidosis various non-specific abnormalities are common (Table 2). There is progressive reduction in the QRS amplitude with disease progression (which is accompanied by progressive thickening of the myocardium on imaging). The presence of low voltage (<0.5 mV) complexes in the limb leads therefore provides a clue. This is often accompanied by marked axis deviation and first-degree heart block.²⁸ Interestingly, most patients remain in sinus rhythm with normal QRS width – due to an unexplained tendency for amyloid fibrils to be deposited within the His-Purkinje system rather than the AV node.¹¹ Non-specific ST changes often lead to the more common diagnosis of myocardial ischaemia.

Exercise testing

Exercise testing is a simple means of assessing exertional symptoms of a possible cardiac aetiology. Four of our patients underwent such a stress test. All of the individuals who underwent exercise testing developed non-specific ST changes suggestive of possible underlying coronary disease. Three of these individuals subsequently underwent coronary arteriography and were found to have normal coronary arteries. One patient had a normal myocardial perfusion scan. In all cases the original abnormality was not revisited but perhaps in retrospect should have indicated an underlying cardiomyopathy.

Echocardiography

The echocardiogram typically changes with disease progression (Table 3). Mean left ventricular wall thickness >12 mm, in the absence of hypertension or another cause of left ventricular hypertrophy, is very suggestive of amyloidosis.²⁹ The presence of right ventricular wall thickening without pulmonary pathology and thickening of the valves and interatrial septum further strengthen this argument.³⁰

Doppler studies generally reveal a degree of diastolic dysfunction,³¹ while tissue Doppler imaging indicates that peak early diastolic wall motion velocity is decreased in most walls before the onset of congestive heart failure.³² However, diastolic dysfunction is a common finding in the elderly population and often disregarded – or its relevance misunderstood by the general physician. A reduction in ejection fraction and systolic dysfunction are usually late signs.³³ The Tei index (defined as the sum of the isovolumetric contraction time and isovolumetric relaxation time divided by the ejection time) gives a combined index of systolic and diastolic myocardial performance, and has been shown to relate to clinical outcomes in cardiac amyloidosis.³⁴ Typically the Doppler-derived isovolumetric contraction and relaxation times are prolonged with shortening of the ejection time. It is the combination of low-voltage or pseudo-infarct patterns on the ECG, and increased myocardial thickness with speckling on the echocardiogram, which is specific for cardiac amyloidosis.³⁵

MRI

Several studies indicate that cardiac MRI has a role in discriminating between hypertrophic and restrictive cardiomyopathy.³⁶ The presence of late gadolinium enhancement is said to be a characteristic feature of cardiac amyloidosis.³⁷ The sensitivity of this is, at present, unclear. However, in the future it may have a role to play in improving non-invasive surveillance in patients with known systemic amyloidosis. To date there have been no large studies directly comparing MRI with echocardiography in the diagnosis of cardiac amyloidosis.

Serum amyloid P scintigraphy

Radiolabelled serum amyloid P component scintigraphy is a simple, reproducible method of quantifying the uptake of ¹²³I-labelled serum amyloid into various organs.³⁸ It is diagnostic of amyloid in most patients with AA and AL amyloidosis and fewer with ATTR-type amyloidosis.³⁹ Although it often reveals more widespread organ involvement than is identified clinically, it is not useful in the evaluation of cardiac amyloidosis.

NT-ProBNP

Elevation of the N-terminal pro-brain natriuretic peptide (NT-proBNP) is associated with many cardiac conditions. Very high levels are consistent with cardiac amyloidosis and related to increased mortality.⁴⁰ NT-proBNP has been studied mainly in AL amyloidosis. The most important cause of NT-proBNP elevation in AL amyloidosis is a direct toxic effect of the circulating amyloidogenic light chain, beside ventricular filling pressure and amyloid infiltration.⁴¹ There are suggestions that patients with a hereditary form of amyloidosis (ATTR amyloidosis) affecting the heart have lower levels of NT-proBNP. No patient with cardiac involvement has a normal NT-proBNP, and this is of help in defining the presence of heart involvement in patients who do not have a clear-cut echocardiographic pattern.⁴⁰ Serial measurement of NT-proBNP during chemotherapy in AL amyloidosis suggests that cardiac function can improve rapidly despite echocardiographic appearances remaining unchanged.⁴²

Troponin

Cardiac troponins T and I are highly sensitive and specific biomarkers of myocardial injury. In cardiac amyloidosis, amyloid deposition in the coronary microvasculature and myocyte compression from amyloid infiltration is thought to account for the observed troponin elevations.⁴³ For patients newly diagnosed with AL amyloidosis, the median survival is worse for those in whom the troponin is elevated.⁴⁴

Together, NT-proBNP and cardiac troponins are powerful prognostic determinants in AL amyloidosis and have been suggested as a method for staging the disease.^{45,46}

Tissue diagnosis

The definitive diagnosis of amyloidosis requires a tissue biopsy demonstrating the classical apple-green birefringence with Congo red stain when viewed under a polarised microscope. In the presence of typical echocardiographic appearances, endomyocardial biopsy is not necessary providing a histological diagnosis has been made from another tissue.⁴⁷ Abdominal fat fine-needle aspiration is positive for amyloid in more than 70% of patients with AL amyloidosis.^{48,49} However, if clinical suspicion remains high despite negative peripheral biopsy, endomyocardial biopsy is indicated. In the correct hands this a safe and simple procedure with a high sensitivity as amyloid is deposited widely through the cardiac tissues.^{50,51} In this case series several patients (Cases 1, 3 and 6) had cardiac biopsies when tissue diagnosis had already been made, putting patients at unnecessary risk.

As mistyping of amyloidosis can lead to therapeutic mistakes, accurate tissue typing is required. Light microscopy immunohistochemistry has a low specificity, particularly in AL amyloidosis, and should be used with great caution for typing. It can also result in false positive results due to serum proteins detected in the tissues which are not related to amyloid, or false negatives due to cleavage products of the amyloid fibrils losing their epitopes or having a different structure to their precursor proteins.⁵² Immunoelectron microscopy can be used to distinguish contaminated labelled protein structures and can detect amyloid when histochemical stains such as Congo red are still negative.⁵³

Making the diagnosis

In uncommon multi-system disorders such as amyloidosis, it is only clinical suspicion that allows early diagnosis. Breathlessness without left ventricular systolic dysfunction all too often leads us towards a respiratory diagnosis. However, signs or symptoms of heart failure in individuals with normal left ventricular systolic function may indicate an infiltrative process. Marked ventricular hypertrophy on the echocardiogram in the presence of small QRS complexes should similarly point to the possibility of amyloidosis (Case 7). Likewise, a strongly positive exercise test with normal coronary arteries should raise suspicion of heart muscle disease (Case 1). It is vital that abnormal cardiac investigations are carefully interpreted within their clinical context.

CONCLUSION

Symptoms and signs of heart failure with preserved left ventricular systolic function in the early stages of presentation are a common theme in this case series. Later, with disease progression, clinical and echocardiographic features of restrictive left ventricular filling pattern and low voltage complexes on the ECG emerge as more specific findings.

Definitive diagnosis of amyloidosis requires a tissue biopsy. Cardiac biopsy is not always necessary, providing a histological diagnosis can be made from other tissues with typical features on echocardiography supporting cardiac involvement. Magnetic resonance imaging and measurement of NT-proBNP may be helpful adjuncts to our assessment in the future.

Cardiac amyloidosis is a progressive disabling disease with a poor prognosis. Our experience over a 12-month period has emphasised the importance of reviewing previous investigations and comparing current clinical status and ECG with previous records. Uncommon disorders such as amyloidosis require a systematic approach and clinical awareness to enable early diagnosis and therapy.

REFERENCES

- 1 Sipe JD, Cohen AS. Review: history of the amyloid fibril. *J Struct Biol* 2000; 130:88–98.
- 2 Kyle RA. Amyloidosis: a convoluted story. *Br J Haematol* 2001; 114:529–38.
- 3 Weber H. Mollities ossium, doubtful whether carcinomatous or syphilitic. *Trans Pathol Soc London* 1867; 18:206–10.
- 4 Baethge BA, Jacobson DR. Amyloidosis, overview. *eMedicine* 2006. Available from: <http://www.emedicine.com/med/topic3377.htm>
- 5 Guidelines Working Group of the UK Myeloma Forum. Guidelines on the diagnosis and management of AL amyloidosis. *Br J Haematol* 2004; 125:681–700.
- 6 Selvanayagam JB, Hawkins PN, Paul B et al. Evaluation and management of the cardiac amyloidosis. *J Am Coll Cardiol* 2007; 50:2101–10.
- 7 Smith TJ, Kyle RA, Lie JT. Clinical significance of histopathologic patterns of cardiac amyloidosis. *Mayo Clin Proc* 1984; 59:547–55.
- 8 Mueller PS, Edwards VD, Gertz MA. Symptomatic ischemic heart disease resulting from obstructive intramural coronary amyloidosis. *Am J Med* 2000; 109:181–8.
- 9 Dubrey SW, Cha K, Skinner M et al. Familial and primary (AL) cardiac amyloidosis: echocardiographically similar diseases with distinctly different outcomes. *Heart* 1997; 78:74–82.
- 10 Santarone M, Corrado G, Tagliagambe LM et al. Atrial thrombosis in cardiac amyloidosis: diagnostic contribution of transesophageal echocardiography. *J Am Soc Echocardiogr* 1999; 12(6):533–6.
- 11 Reisinger J, Dubrey SW, Lavalley M et al. Electrophysiologic abnormalities in AL (primary) amyloidosis with cardiac involvement. *J Am Coll Cardiol* 1997; 30:1046–51.
- 12 Parikh S, de Lemos JA. Current therapeutic strategies in cardiac amyloidosis. *Curr Treat Options Cardiovasc Med* 2005; 7(6):443–8.
- 13 Rubinow A, Skinner M, Cohen AS. Digoxin sensitivity in amyloid cardiomyopathy. *Circulation* 1981; 63:1285–8.
- 14 Gertz MA, Lacy MQ, Dispenzieri A. Amyloidosis. *Hematol Oncol Clin North Am* 1999; 13:1211–33.
- 15 Buja LM, Kholi NB, Roberts WC. Clinically significant cardiac amyloidosis. Clinicopathologic findings in 15 patients. *Am J Cardiol* 1970; 26:394–405.
- 16 Pollak A, Falk RH. Left ventricular systolic dysfunction precipitated by verapamil in cardiac amyloidosis. *Chest* 1993; 104:618–20.
- 17 Low PA, Gilden JL, Freeman R et al. Efficacy of midodrine versus placebo in neurogenic orthostatic hypotension: a randomised, double-blind multicenter study. *JAMA* 1997; 277:1046–51.
- 18 Goodman HJ, Gillmore JD, Lachmann HJ et al. Outcome of autologous stem cell transplantation for AL amyloidosis in the UK. *Br J Haematol* 2006; 134:417–25.
- 19 Lachmann HJ, Gallimore R, Gillmore JD, et al. Outcome in systemic AL amyloidosis in relation to changes in concentration of circulating free immunoglobulin light chains following chemotherapy. *Br J Haematol* 2003; 122:78–84.
- 20 Moreau P, Leblond V, Bourquelot P et al. Prognostic factors for survival and response after high dose therapy and autologous stem cell transplantation in systemic AL amyloidosis: a report on 21 patients. *Br J Haematol* 1998; 101:766–9.
- 21 Saba N, Sutton D, Ross H et al. High treatment-related mortality in cardiac amyloid patients undergoing autologous stem cell transplant. *Bone Marrow Transplant* 1999; 24:853–5.
- 22 Kyle RA, Gertz MA, Greipp PR et al. A trial of three regimens for primary amyloidosis: colchicine alone, melphalan and prednisolone, and melphalan, prednisolone and colchicines. *N Eng J Med* 1997; 336:1202–7.
- 23 Gilmore JD, Lovat LB, Persey MR et al. Amyloid load and clinical outcome in AA amyloidosis in relation to circulating concentration of serum amyloid A protein. *Lancet* 2001; 358:24–9.
- 24 Gottenberg JE, Merle-Vincent F, Bentaberry F et al. Anti-tumor necrosis factor alpha therapy in fifteen patients with AA amyloidosis secondary to inflammatory arthritides: a follow up report of tolerability and efficacy. *Arthritis Rheum* 2003; 48:2019–24.
- 25 Dember LA, Hawkins PN, Hazenberg BP et al. Eprodisate for the treatment of renal disease in AA amyloidosis. *N Eng J Med* 2007; 356:2349–60.
- 26 Maurer MS, Raina A, Hesdorffer C et al. Cardiac transplantation using extended-donor criteria organs for systemic amyloidosis complicated by heart failure. *Transplantation* 2007; 83:539–45.
- 27 Gillmore JD, Goodman HJ, Lachmann HJ et al. Sequential heart and autologous stem cell transplantation for systemic amyloidosis. *Blood* 2006; 107:1227–9.
- 28 Murtagh B, Hammill SC, Gertz MA et al. Electrocardiographic findings in primary systemic amyloidosis and biopsy-proven cardiac involvement. *Am J Cardiol* 2005; 95:535–7.
- 29 Klein AL, Hatle LK, Burstow DJ et al. Doppler characterization of left ventricular diastolic function in cardiac amyloidosis. *J Am Coll Cardiol* 1989; 13: 1017–26.
- 30 Siqueira-Filho AG, Cunha CLP, Tajik AJ et al. M-mode and two-dimensional echocardiographic features in cardiac amyloidosis. *Circulation* 1981; 63:188–96.
- 31 Klein AL, Cohen GI. Doppler echocardiographic assessment of constrictive pericarditis, cardiac amyloidosis and cardiac tamponade. *Cleveland Clin J Med* 1992; 59:278–90.
- 32 Koyama J, Ray-Sequin PA, Davidoff R et al. Usefulness of pulsed tissue Doppler imaging for evaluating systolic and diastolic left ventricular function in patients with AL (primary) amyloidosis. *Am J Cardiol* 2002; 89:1067–71.
- 33 Falk RH. Cardiac amyloidosis. *Prog Cardiol* 1989; 2:143–55.
- 34 Tei C, Dujardin KS, Hodge DO et al. Doppler index combining systolic and diastolic myocardial performance: clinical value in cardiac amyloidosis. *J Am Coll Cardiol* 1996; 28(3):658–64.
- 35 Rahman JE, Helou EF, Gelzer-Bell R et al. Non-invasive diagnosis of biopsy-proven cardiac amyloidosis. *J Am Coll Cardiol* 2004; 43(3):410–5.
- 36 Celletti F, Fattori R, Napoli G et al. Assessment of restrictive cardiomyopathy of amyloid or idiopathic aetiology by magnetic resonance imaging. *Am J Cardiol* 1999; 83:798–801, A10.
- 37 Maceira AM, Joshi J, Prasad SK et al. Cardiovascular magnetic resonance in cardiac amyloidosis. *Circulation* 2005; 111:186–93.
- 38 Hawkins PN, Richardson S, MacSweeney JE et al. Scintigraphic quantification and serial monitoring of human visceral amyloid deposits provide evidence for turnover and regression. *Q J Med* 1993; 86:365–74.
- 39 Hazenberg BPC, van Rijswijk MH, Piers DA et al. Diagnostic performance of 123I-labeled serum amyloid P component scintigraphy in patients with amyloidosis. *Am J Med* 2006; 119:355e15–24.

- 40 Palladini G, Campana C, Klersy C et al. Serum N-terminal pro-brain natriuretic peptide is a sensitive marker of myocardial dysfunction in AL amyloidosis. *Circulation* 2003; 107:2440–5.
- 41 Nordlinger M, Magnani B, Skinner M et al. Is elevated B-natriuretic peptide in amyloidosis simply a function of the presence of heart failure? *Am J Cardiol* 2005; 96:982–4.
- 42 Palladini G, Lavatelli F, Russo P et al. Circulating amyloidogenic free light chains and serum N-terminal natriuretic peptide type B decreases simultaneously in association with improvement of survival in AL amyloid. *Blood* 2006; 107:3854–8.
- 43 Cantwell RV, Aviles RJ, Bjornsson J et al. Cardiac amyloidosis presenting with elevations of cardiac troponin I and angina pectoris. *Clin Cardiol* 2002; 25:33–7.
- 44 Dispenzieri A, Kyle RA, Gertz MA et al. Survival in patients with primary systemic amyloidosis and raised serum cardiac troponins. *Lancet* 2003; 361:1787–9.
- 45 Dispenzieri A, Gertz MA, Kyle RA et al. Prognostication of survival using cardiac troponins and N-terminal pro-brain natriuretic peptide in patients with primary systemic amyloidosis undergoing peripheral blood stem cell transplantation. *Blood* 2004; 104:1881–7.
- 46 Dispenzieri A, Gertz MA, Kyle RA et al. Serum cardiac troponins and N-terminal pro-brain natriuretic peptide: a staging system for primary systemic amyloidosis. *J Clin Oncol* 2004; 18:3751–7.
- 47 Falk RH, Plehn JF, Deering T et al. Sensitivity and specificity of the echocardiographic features of cardiac amyloidosis. *Am J Cardiol* 1987; 59:418–22.
- 48 Libbey CA, Skinner M, Cohen AS. Use of abdominal fat tissue aspirate in the diagnosis of systemic amyloidosis. *Arch Intern Med* 1983; 143:1549–52.
- 49 Ansari-Lari MA, Ali SZ. Fine-needle aspiration of abdominal fat pad for amyloid detection: a clinically useful test? *Diagn Cytopathol* 2004; 30:178–81.
- 50 Ardehali H, Qasim A, Cappola T et al. Endomyocardial biopsy plays a role in diagnosing patients with unexplained cardiomyopathy. *Am Heart J* 2004; 147:919–23.
- 51 Gertz MA, Grogan M, Kyle RA et al. Endomyocardial biopsy-proven light chain amyloidosis (AL) without echocardiographic features of infiltrative cardiomyopathy. *Am J Cardiol* 1997; 80:93–5.
- 52 Rocken C, Sletten K. Amyloid in surgical pathology. *Virchows Arch* 2003; 443:3–16.
- 53 Arbustini E, Morbini P, Verga L et al. Light and electron microscopy immunohistochemical characterization of amyloid deposits. *Amyloid* 1997; 4:157–70.

UPCOMING EDITORIAL VACANCIES AT THE JOURNAL

Editor and Clinical Section Editor

The Journal of the Royal College of Physicians of Edinburgh

Expressions of interest are invited for the above posts from Fellows. Both positions are honorary and will become available in March 2009, with a handover period until June 2009. Support is provided by an experienced production staff of three within the College.

The *Journal* is a quarterly 96-page publication consisting of three sections – Clinical, Education and History. It has a circulation of about 8,000, including all Fellows and Collegiate Members and some postgraduate libraries.

The **Editor** is responsible for the strategic direction of the *Journal* and for planning each issue. He or she works together with the three Section Editors to ensure high scientific and editorial standards and that work is carried out in accordance with editorial policies and good publishing practices. He or she is also responsible for commissioning editorials and clinical opinions, as well as arranging replies to letters to the Editor. The Editor reports to Council and has final editorial control over what goes into the *Journal*.

The **Clinical Section Editor** is responsible for refereeing, revising/editing and selecting submitted papers, and occasionally commissioning papers, for the Clinical section of the *Journal* (approx. 40 pages per quarter), ensuring a high standard and adequate flow of papers. He or she is also responsible for the editing of symposium reports and abstracts, and represents the *Journal* on the Symposium Committee.

Applicants for both posts will require good communication skills, a knowledge of the writing and editing of scientific articles and sufficient time to deal promptly with editorial decisions.

For further information, please contact:

Graeme McAlister, Head of Fellowship and Membership Services, Royal College of Physicians of Edinburgh, 9 Queen Street, Edinburgh EH2 1JQ, UK

Tel: +44 (0)131 247 3693

Email: g.mcalister@rcpe.ac.uk

Full job descriptions are available online at: www.rcpe.ac.uk (under 'What's new')

Closing date: 2 November 2008

RCPE 
Royal College of Physicians of Edinburgh