

Fetal surgical intervention

¹CR Welch, ²L Dupuch

¹Consultant in Fetal Medicine; ²Specialist Registrar in Obstetrics and Gynaecology, Derriford Hospital, Plymouth, Devon, UK

ABSTRACT Developments in medicine have enabled some surgical procedures to be carried out on fetuses while they are still inside the mother's womb with the intent of saving the life of the fetus or minimising serious disease. In this article, the authors review these developments and the range of surgical procedures currently being carried out.

KEYWORDS Fetal diseases, fetal surgery, fetal therapy

LIST OF ABBREVIATIONS Atrio septal defects (ASDs), cystic adenomatoid malformation of the lung (CCAML), ex utero intrapartum treatment (EXIT), Management of Meningomyelocele Study (MOMs), magnetic resonance imaging (MRI), National Institute of Clinical Excellence (NICE), National Institutes of Health (NIH), twin reversed arterial perfusion (TRAP), twin to twin transfusion syndrome (TTTS)

DECLARATION OF INTERESTS No conflict of interests declared.

Intrauterine intervention for fetal disease has been happening for more than 40 years, particularly fetal transfusion for alloimmune anaemia. The first direct intravascular fetal transfusion was in 1984, but intraperitoneal transfusion had been practiced for some years before that. During the last two decades, fewer new procedures have been proposed, but much work has taken place on assessing which procedures should continue to be performed, and also how, on whom, and when.

FETAL TRANSFUSION

The indications for *in utero* treatment of alloimmune red cell and platelet disease have been settled since the early 1990s. Fetal transfusion techniques improved when the haemorheologic implications were elucidated and needle modifications to improve flow and decrease clot formation were designed.^{1,2} Management plans have continued to improve, however, with routine non-invasive detection of rhesus and kell fetal blood group, from maternal blood samples and improved detection of fetal anemia with fetal cerebral artery blood velocity measured by Doppler. These developments have led to fewer fetuses being put at risk by unnecessary fetal blood sampling and fewer units of expensively prepared special transfusion blood being wasted.

FETAL SHUNTING

Drainage of various abnormal intra-fetal fluid collections has been described including from cerebral ventricles, cystic hygromata, pleural cavity, lung cysts, bladder, renal

pelvis, peritoneum and cystic tumours, all into the amniotic fluid. Currently, the only procedures still in regular use are pleuro-amniotic and vesico-amniotic shunting. Both of these procedures have recently been the subject of reviews and advice (available online – see references) by NICE.^{3,4}

Despite all the research and clinical practice to date, the place of vesico-amniotic shunting for lower urinary tract obstruction (posterior urethral valves or urethral atresia) is still in question. No randomised controlled studies have been performed, but one has just commenced.⁵ NICE have also recently issued guidance and advice about direct intrauterine fetal cystoscopy.⁶ This technique, pioneered by Quintero in the early 1990s, has had very little world wide use and only one publication from Europe, which is included in the NICE assessment.

ACARDIAC TWINNING

The *in utero* treatment of pregnancies complicated by the presence of an acardiac twin of significant size has become clear. The blood supply to the acardiac twin should be interrupted early to avoid the demise, through high output cardiac failure, of the normal co-twin (TRAP sequence). There have been a number of approaches to this. Fetoscopically directed laser ablation and ultrasound guided diathermy with 3mm bipolar diathermy forceps applied directly to the umbilical cord are the most published, but there are reports using insterstitial laser and radio frequency devices, inserted just inside the acardiac's umbilicus to ablate the vessels entering the root of the umbilical cord.

Published online August 2007

Correspondence to CR Welch,
Lancaster Suite, Level 6, Maternity
Department, Derriford Hospital
Plymouth, Devon PL8 6DH, UK

tel. +44 1752 792769

fax. +44 (0)44 1752 763721

e-mail rosswelch@mac.com

TWIN TO TWIN TRANSFUSION SYNDROME (TTTS)

Twin to twin (Fetofetal transfusion, twin oligo-polyhydramnios) is one area where real *in utero* progress has been made. The morbidity and mortality of TTTS is very high if left untreated, particularly at early gestation where delivery is not a realistic option. Therapeutic interventions have progressed, through amnioreduction of the polyhydramniotic sac, simple septostomy,⁷ non-selective, and finally selective fetoscopic, laser ablation of placental vessels. Pioneered by De Lia in the late 1980s, several observational studies and at least one randomised study have clarified that, for Quintero, stage 3 and 4, selective fetoscopic laser ablation has the best overall survival and the least long-term morbidity for the survivors.^{8,9} The discovery of significant infant cardiac dysfunction and hypertension in survivors which is ameliorated by laser treatment, but not by amnioreduction, shows that simple survival is no longer the target in this area, and that research has not stopped but continues to develop better treatment strategies. The threshold for intervention by fetoscopic laser and the alternatives for earlier stages of TTTS have yet to be fully elucidated.

SPINA BIFIDA

The first 'repair' of spina bifida *in utero* was presented at the International Fetal Medicine and Surgery Society in 1997. The theory is that exposure of spinal nerve material to amniotic fluid causes progressive damage resulting in a worse outcome the longer the fetus is *in utero*. Simply closing or covering the lesion early in gestation should reduce the damage. To date, animal and human research has shown likely benefits in reducing or resolving the Chiari malformation of the cerebellum and a probable reduction in the number of children requiring ventriculo-peritoneal shunts or at least delaying the first insertion of a shunt. The current NIH-funded MOMs randomised trial in the US¹⁰ should reach a conclusion soon.

DIAPHRAGMATIC HERNIA

The development of diagnostic and management strategies for congenital diaphragmatic hernia and to a lesser extent, CCAML are mirrors for much of fetal surgery. Pioneered by Mike Harrison at the Fetal Treatment Centre at the University of California, San Francisco, treatment approaches started with a single stage full diaphragmatic repair via a hysterotomy, progressed through extensive research with fetoscopic surgery to ligate or clip the trachea, to the current fetoscopic placement of an occlusive tracheal balloon. The process of appropriate patient selection (liver herniation into chest, lung to head ratio <1.0), basic science experimentation to show that 'plugged' lungs developed into functioning lungs and the microinvasive

surgical techniques and equipment to enable balloon placement have all coalesced, resulting in a clear treatment strategy supported by randomised trials.^{11,12} The current approach would not have been possible without concomitant improvements in MRI and ultrasound to allow better fetal imaging. Equally, the development of surgical techniques such as the EXIT procedure have improved the transfer to *ex utero* life. EXIT procedures are now established for situations where there is expected to be significant airway compromise at delivery, caused by neck masses or tumours.

Cystic adenomatoid malformation of the lung management has developed in parallel to identify the small percentage of patients who may benefit from *in utero* open surgical removal of the tumour because of incipient or established hydrops.

MISCELLANEOUS

There are a number of other areas of direct fetal surgical therapy still being developed, the development often constrained by the rarity of the condition being treated and the number of centres able and willing to attempt new treatments and research them. Fetal cardiac lesions have been treated with varying success rates, from creating larger ASDs in hypoplastic left heart syndrome through balloon or radio frequency therapy to stenotic or atretic aortic and pulmonary valves and direct fetal pacing for congenital heart block.¹³ Sacrococcygeal tumours have been successfully treated by open resection, radio frequency ablation of feeding vessels and shunting to reduce their volume. The mainstay of therapy being to reduce or reverse fetal hydrops.

ONGOING CHALLENGES

The biggest single challenge to most of the approaches above has been the problem of entering the amniotic cavity and leaving it 'watertight' at the end. Post-procedure leakage of amniotic fluid, often followed by previsible or very preterm delivery remains the most difficult obstacle to overcome. Preterm labour has been greatly improved by reduction in instrument size or degree of intervention, combined with modern tocolytic (contraction stopping) drugs, but we still have to solve the problem of sealing a hole in an avascular membrane that has no intrinsic self-healing mechanism. The best hopes to date involve biological glues such as the amniopatch procedure.¹⁴

THE FUTURE

To date the majority of intrauterine fetal surgical therapies have been directed at structural fetal anomalies with the aim being to resolve them prenatally or perhaps to optimise fetal condition long enough to allow growth

CR Welch, L Dupuch

and development in utero to a stage where delivery and definitive post natal treatment is possible. The great hope for the future is treatment of medical conditions such as cystic fibrosis and Huntingdon's by gene transplant or

haematological and other disorders with stem cell transplantation. The research is well under way and we look forward to a continually developing future *in utero* fetal surgery and medicine.

KEYPOINTS

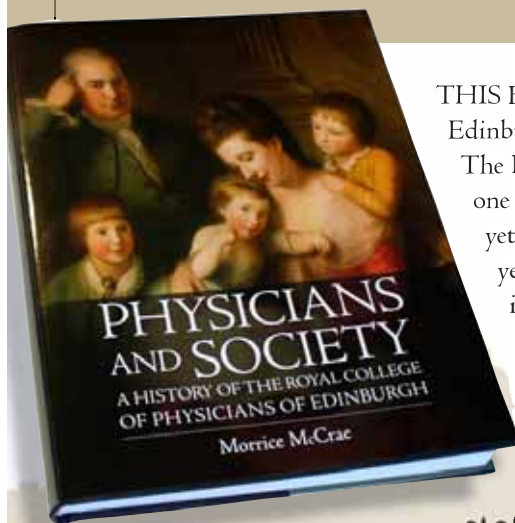
- Fetal surgery has progressed to include transfusion and direct surgical interventions.
- Currently, only pleuro-amniotic and vesico-amniotic shunting are undertaken regularly.
- Acardiac twin ablation of blood supply is performed with either laser ablation or ultrasound guided diathermy.
- The effectiveness of spina bifida repair, intrauterine cardiac fetal surgery and tumour surgery are at an early stage of assessment.
- Post-procedure leakage of amniotic fluid leading to preterm delivery remains a significant problem.

REFERENCES

- 1 Welch CR, Rampling MW, Anwar MA, Talbert DG, Rodeck CH. Changes in hemo-rheology with fetal intravascular transfusion. *Am J Obstet Gynecol* 1994; **170**:726–32.
- 2 Welch CR, Talbert DG, Warwick RM, Letsky EA, Rodeck CH. Needle modifications for invasive fetal procedures. *Obstet Gynecol* 1995; **85**:113–7.
- 3 http://www.nice.org.uk/page.aspx?o=IP_333 (Pleuro-amniotic shunting)
- 4 <http://www.nice.org.uk/guidance/IPG202> (Vesico-amniotic shunting)
- 5 <http://www.pluto.bham.ac.uk> (PLUTO Trial)
- 6 <http://www.nice.org.uk/guidance/IPG205> (Fetal cystoscopy)
- 7 <http://www.nice.org.uk/guidance/IPG199> (Septostomy)
- 8 <http://www.nice.org.uk/guidance/ipg198/?c=91520c> (TTTS Laser)
- 9 Senat MV, Deprest J, Boulvain M, Paupe A, Winer N, Ville Y. Endoscopic laser surgery versus serial amnioreduction for severe twin-to-twin transfusion syndrome. *N Engl J Med* 2004; **351**(2):136–414.
- 10 <http://www.spinabifidamoms.com/english/index.html>
- 11 Harrison MR, Keller RL, Hawgood SB et al. A randomized trial of fetal endoscopic tracheal occlusion for severe fetal congenital diaphragmatic hernia. *N Engl J Med* 2003; **349**(20):1916–24.
- 12 Deprest J, Jani J, Gratacos E et al. FETO Task Group. Fetal intervention for congenital diaphragmatic hernia: the European experience. *Semin Perinatol* 2005; **29**(2):94–103.
- 13 Walkinshaw SA, Welch CR, Walsh K, McCormack J. *In utero* pacing for fetal congenital heart block. *Fet Diagn Ther* 1994; **9**:183–5.
- 14 Lewi L, Van Schoubroeck D, Van Ranst M et al. Successful patching of iatrogenic rupture of the fetal membranes. *Placenta* 2004; **25**:352–6.

PHYSICIANS AND SOCIETY

A History of the Royal College of Physicians of Edinburgh • MORRICE MCCRAE



THIS BOOK is a social history of the Royal College of Physicians of Edinburgh from its foundation in 1681 until 1918.

The Royal College of Physicians of Edinburgh was founded during one of the most disturbed and violent periods in Scottish History, yet it survived the religious and political conflicts of its early years to become the most influential medical and scientific body in Scotland. Fellows of the College created what became the foremost medical school in Europe and the English-speaking world.

£25.00

Hardback 246 x 189 mm, Colour illustrations throughout

ISBN 13: 978 0 85976 698 2



Further information from:
BIRLINN LTD, West Newington House, 10 Newington Road,
Edinburgh EH9 1QS Phone order line: +44 (0) 131 667 7799
Or visit the Birlinn website at www.birlinn.co.uk