

Rounded atelectasis mimicking a lung cancer

ARL Medford,¹ M Darby,² NA Maskell³

¹Special registrar in Respiratory Medicine, Respiratory Medicine Department, Southmead Hospital, Bristol, England, ²Consultant Radiologist, Department of Radiology, Southmead Hospital, Bristol, England ³Consultant Physician in Respiratory and General Medicine, Respiratory Medicine Department, Southmead Hospital, Bristol, England

ABSTRACT This short report illustrates a case of a 70-year-old ex-smoker who worked with asbestos presenting with an abnormal chest x-ray suspicious for lung cancer on initial appearance. However, subsequent investigations confirmed RA, a well recognised pleural condition associated with asbestos. The historical background of RA, its pathogenesis and imaging characteristics are reviewed. Rounded atelectasis remains an important differential diagnosis to consider in asbestos-exposed individuals with an abnormal chest x-ray. Correct diagnosis has important implications for management and avoidance of unnecessary surgical staging and treatment for presumed lung cancer.

KEYWORDS Asbestos, Blesovsky's syndrome, lung cancer, pleural disease, rounded atelectasis

LIST OF ABBREVIATIONS Computerised tomography (CT), rounded atelectasis (RA)

DECLARATION OF INTERESTS No conflict of interests declared.

INTRODUCTION

The incidence of asbestos-related lung disease continues to increase and is frequently encountered by general physicians as well as respiratory specialists. It is therefore important for general physicians to have an awareness of benign asbestos-related lung disease that may mimic more serious but common lung disease such as lung cancer that carries significant implications when diagnosed.

CASE HISTORY

A 70-year-old man presented with atypical dyspeptic-sounding chest pain and moderate weight loss. He had a 25 pack year smoking history and had been exposed to asbestos from 1967–76 while working as a decorator for a building firm on multiple sites alongside tradesmen who ripped out asbestos. From 1979–89 he worked as a painter and decorator maintaining old buildings. Twenty years previously, he had been investigated by a respiratory physician for an incidental finding on chest x-ray with normal bronchoscopy and no progressive radiographic changes over two years. His old films were not available for comparison and there was no evidence of a previous CT scan being performed.

Physical examination was unremarkable and spirometry reasonable (3.05/3.5). His current chest x-ray was abnormal showing a left sided intrapulmonary neoplasm and some pleural plaques in keeping with his asbestos exposure (see Figure 1). Because of the weight loss, smoking history and radiographic abnormalities (and the unavailability of

previous imaging), he was investigated further with bronchoscopy and a CT scan which showed no evidence of malignancy. The CT scan did however confirm the presence of a left-sided 4 cm mass (see Figure 2A) and enfolded lung with a 'comet tail' appearance (see Figure 2B) consistent with RA, as well as pleural plaques but no mediastinal adenopathy (figures 2A–C). At a further clinic review, he had more than replaced his weight loss (in retrospect this may have been entirely due to reduced appetite because of his dyspeptic chest pain). A barium swallow was entirely normal and his dyspeptic symptoms settled spontaneously without the need for treatment. Serial chest x-rays have remained entirely unchanged (over two years) with no new worrisome

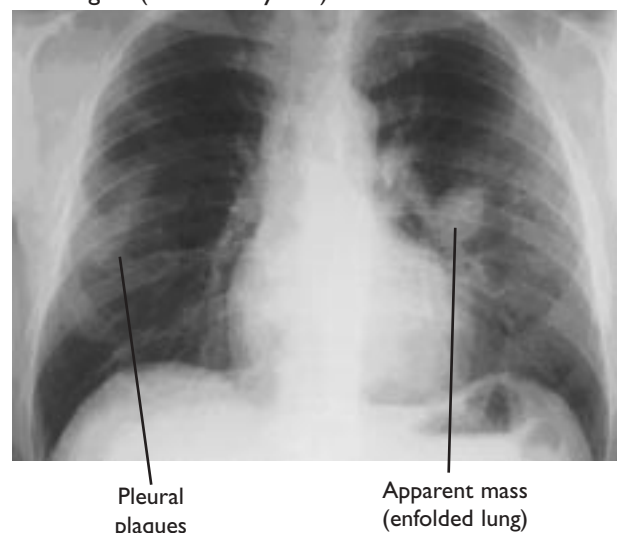


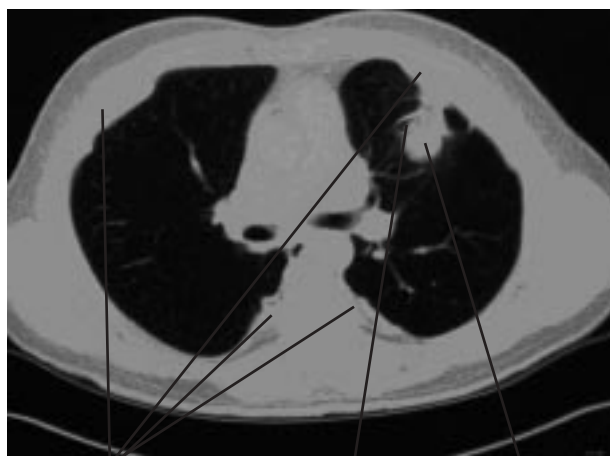
FIGURE 1 CXR showing apparent left midzone mass.

Correspondence to ARL Medford, Respiratory Medicine Department, Southmead Hospital, Westbury-on-Trym, Bristol, BS10 5NB

tel. +44 (0)117 959 6242

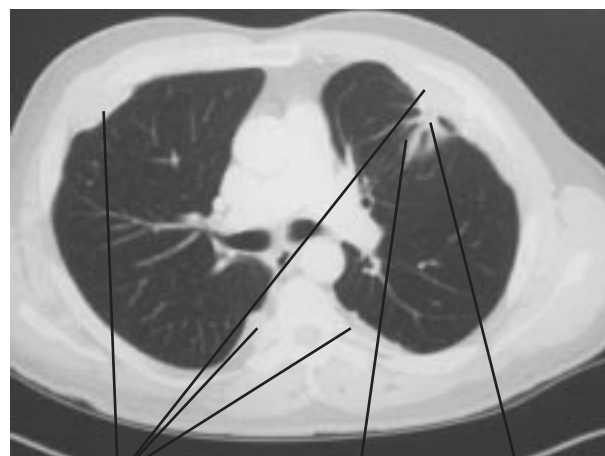fax. +44 (0)117 959 6243

e-mail Andrew.Medford@bris.ac.uk



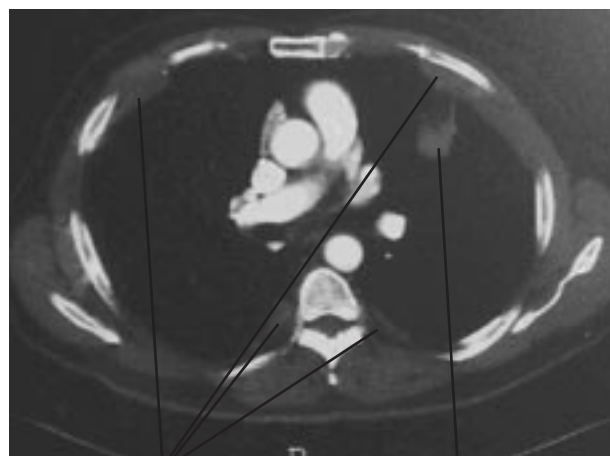
Pleural plaques and thickening
Comet tail (vessels and bronchi)
Apparent mass (enfolding lung)

FIGURE 2A CT scan (lung and mediastinal windows) showing enfolding lung and 'comet tail' appearance.



Pleural plaques and thickening
Comet tail (vessels and bronchi)
Apparent mass (enfolding lung)

FIGURE 2B CT scan (lung and mediastinal windows) showing enfolding lung and 'comet tail' appearance.



Pleural plaques and thickening
Apparent mass (enfolding lung)

FIGURE 2C CT scan (lung and mediastinal windows) showing enfolding lung and 'comet tail' appearance.

symptoms or signs.

Rounded atelectasis was originally described in 1928 by Loeschke.¹ In 1966, Blesovsky postulated an association between rounded atelectasis and asbestos exposure (responsible for about 70% of RA cases) coining the term Blesovsky's syndrome.² He described specific radiological features of a peripheral, laminar lesion with radiations and a thickened membrane enfolding otherwise normal lung at thoracotomy with occasional pleural plaques.² Other terms used have included 'shrinking pleuritis' and 'pulmonary pseudotumour'.^{3,4} It can also occur in pleural tuberculosis, Dressler's syndrome, cardiac failure, post-

traumatic haemorrhagic effusion and therapeutic pneumothorax and has been described complicating Legionella pneumonia.⁵⁻⁹

Rounded atelectasis is a benign condition with a localised, but usually peripheral, area of collapsed lung parenchyma surrounded partly by invaginated thickened pleura. Its pathogenesis remains unclear, although it usually reflects visceral pleural fibrosis. It is thought to occur either due to trapping and infolding of poorly expanded lung at the periphery by fibrinous adhesions following pleural effusion⁷ or by visceral pleural fibrosis following pleuritis.³ Other theories involving other factors have been proposed.

Imaging of RA typically shows a 2–5 cm pleural-based rounded lesion in the lower lobes with pleural effusion or thickening and a characteristic 'comet tail' appearance due to the distorted course of vessels and bronchi entering the atelectatic portion of lung.¹⁰ Only a minority of RA cases continue to progress in size and require evaluation for malignancy or, more rarely, decortication if symptomatic from the pleural fibrosis.⁷ More recent mineralogical data suggest a high concentration of asbestos bodies in bronchoalveolar lavage in RA patients related to asbestos exposure even in the absence of diffuse pleural thickening or asbestosis.¹¹

CONTRIBUTIONS

ARL Medford and NA Maskell conceived the idea. ARL Medford did the literature search and wrote the manuscript with input from M Darby and NA Maskell. The images were reviewed by M Darby.

REFERENCES

- 1 Loeschke H. Störungen des luftgehalts der lunge. In: *Henke-Lubarsch XX, ed. Handbuch der speziellen pathologischen anatomie und histologie IIIII*. Berlin: Springer; 1928;599.
- 2 Blesovsky A. The folded lung. *Br J Dis Chest* 1966; **60**:19–22.
- 3 Dernevik L, Gatzinsky P, Hultman E et al. Shrinking pleuritis with atelectasis. *Thorax* 1982; **37**:252–8.
- 4 Payne CR, Jacques P, Kerr IH. Lung folding simulating peripheral pulmonary neoplasm (Blesovsky's syndrome). *Thorax* 1980; **35**:936–40.
- 5 Hillerdal G. Rounded atelectasis. Clinical experience with 74 patients. *Chest* 1989; **95**:836–41.
- 6 Stark P. Round atelectasis: another pulmonary pseudotumour. *Am Rev Respir Dis* 1982; **125**:248–50.
- 7 Hanke R, Kretzschmar R. Round atelectasis. *Semin Roentgeno* 1980; **15**:174–82.
- 8 Papis SA, Maniati MA, Sakellariou K et al. Round atelectasis and Metsovo lung. *Chest* 1993; **103**:1759–62.
- 9 Kuno R, Bower DJ, Aguayo SM. Round atelectasis as a complication of Legionella pneumonia. *Chest* 1994; **106**:607–8.
- 10 Partrap VA. The comet tail sign. *Radiology* 1999; **213**:553–4.
- 11 Voisin C, Fisecki F, Voisin-Saltiel V et al. Asbestos-related rounded atelectasis. *Chest* 1995; **107**:477–81.