

CASE REPORT: FATAL NON-RENAL WEGENER'S GRANULOMATOSIS

N. Maiden, Specialist Registrar in Rheumatology, Department of Rheumatology; D. Grieve, Consultant Radiologist, Department of Radiology; J. St J. Thomas, NHS Consultant, Department of Pathology; and R. Luqmani, NHS Consultant, Department of Rheumatology; all at the Western General Hospital, Edinburgh

CASE REPORT

A 48-year-old woman with a past history of multiple sclerosis was referred to the rheumatology clinic from the ear, nose and throat department in April 1995. She gave a four month history of nasal stuffiness and crusting, sinus pain, hearing loss, epistaxis and weight loss. She had also noticed that the shape of her nose was changing. On examination, the pertinent findings were a saddle deformity of her nose and bilateral parotid gland swelling; urinalysis was negative. Her serum contained cytoplasmic anti-neutrophil cytoplasmic antibodies (cANCA) on immunofluorescence testing. A biopsy of her nasal mucosa showed chronic inflammation and a right parotid gland biopsy revealed acute inflammatory changes with destruction of the ducts and the presence of giant cell granulomata. A diagnosis of localised (non-renal) Wegener's granulomatosis (WG) was made and she was commenced on continuous oral cyclophosphamide and prednisolone with good response.

Despite her initial improvement, her disease flared on attempting to withdraw immunosuppression after 18 months. She developed severe stridor requiring the insertion of a permanent tracheostomy for subglottic stenosis. In 1997 she was treated with azathioprine which failed to control her disease; when this was changed to high dose parenteral methotrexate (up to 47.5 mg per week) and intermittent courses of intravenous immunoglobulins her general condition improved. She was, however, troubled by a combination of recurrent respiratory tract infections and persistent low grade upper respiratory tract symptoms which worsened over the following two years. Nasal biopsies confirmed the presence of active granulomatosis and vasculitis. In January 2000 she was admitted to hospital with deteriorating respiratory symptoms, and a CT scan of her thorax showed cavitating nodules. She developed respiratory failure requiring admission to the intensive care unit where she was treated with plasma exchange followed by boluses of high dose intravenous cyclophosphamide (15 mg/kg) and methylprednisolone (10 mg/kg). Over the course of the year, she had five further admissions to hospital with severe respiratory infections and required ventilation on one further occasion. During her final admission, despite intensive medical management, she suffered a cardio-respiratory arrest and died. At no stage in her course did she have clinical evidence of renal involvement.

RADIOLOGY

Chest X-rays and a CT scan in 1999 were abnormal but nonspecific, i.e. patchy infiltrates and consolidation, predominantly in the right lower and middle lobes (Figure 1). In January 2000, a conventional spiral and high resolution CT chest scan showed at least three cavities and several pulmonary nodules, the appearances being consistent with WG. The final few months of chest X-rays demonstrated fluctuating areas of consolidation and cavitation, predominantly in the right lung, until the final film showed almost confluent opacification with a large right mid zone cavity (Figure 2). In summary, therefore, her radiology shows the characteristic features of pulmonary Wegener's – multiple pulmonary nodules which wax and wane and show features of cavitation. The consolidation would be consistent with intercurrent infection and/or haemorrhage.

PATHOLOGY

At autopsy there was focal congestion and ulceration of the nasopharyngeal mucosa. There was extensive consolidation and cavitation in both lungs which was particularly marked in the right upper lobe. Both kidneys showed multiple white cortical nodules consistent with previous ischaemia.

Histology of the lungs showed multiple necrotising granulomatous lesions with intervening scarring of lung parenchyma (Figure 3). The granulomata were not based on vascular structures and, while containing moderate numbers of polymorph nuclear cells, did not show significant numbers of eosinophils. The appearances in the lungs were entirely consistent with a diagnosis of WG. Sections of the kidneys showed no evidence of active glomerular disease. There were multiple foci of cortical interstitial scarring and an occasional cortical interstitial microgranuloma was identified, indicating active disease at this site.

DISCUSSION

Wegener's granulomatosis is a systemic vasculitis of the medium and small blood vessels primarily affecting the upper and lower respiratory tracts and the kidneys.^{1,2} A 'limited' form, with the clinical findings restricted to the upper respiratory tract or the lungs, as in this patient, occurs in around one-quarter of cases.^{3,4} Other organ systems may be involved including joints, eyes, skin, nervous system, heart and gastrointestinal tract. The

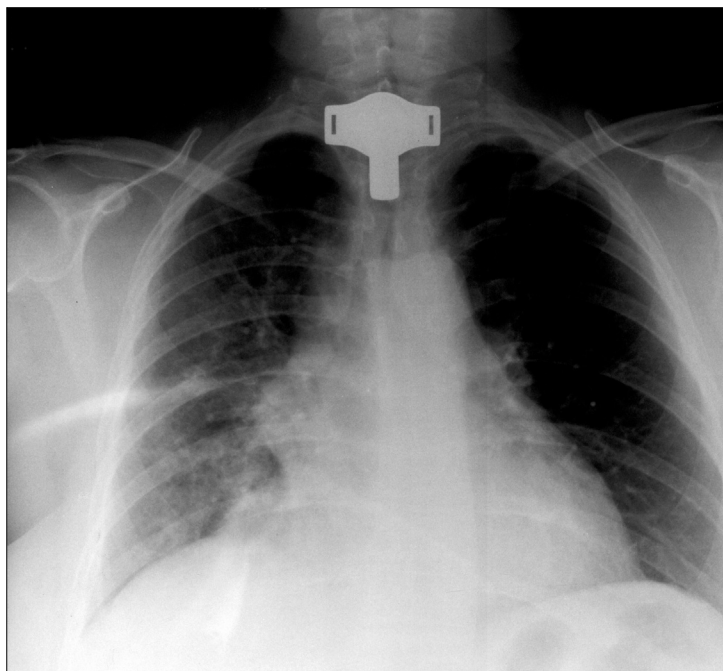


FIGURE 1

A chest X-ray from 1999 showing non-specific patchy infiltrates in the right lung.

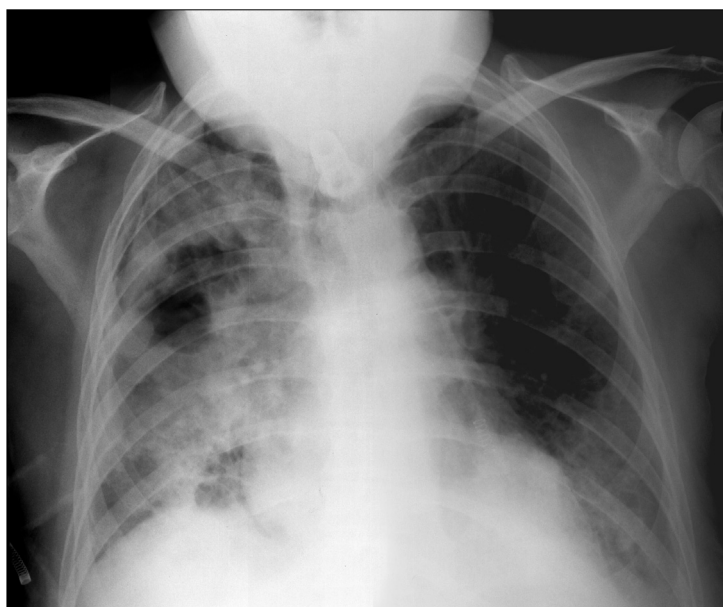


FIGURE 2

A chest X-ray from the final hospital admission showing almost complete opacification of the right lung with a large cavity in the right mid zone.

disease most often presents with nasal discharge/crusting, sinus pain, arthralgia or myalgia. Although 65–90% of patients with active WG have a positive ANCA,⁵ the diagnosis is confirmed by the clinical features and tissue biopsy of an affected site. The prognosis of untreated WG is poor, with up to 90% of patients dying within two years,⁶ but cytotoxic therapy has dramatically improved survival and remissions can be induced in most patients (85–90%) with cyclophosphamide and prednisolone.^{2,7,8} Relapse is a frequent occurrence despite initial good

control.^{7,9} Patient survival is currently over 75% at three to ten years follow-up.^{2,7,10-12} Cyclophosphamide resistance, as in this patient, is rare and there is at present little evidence-based treatment for persistent disease activity that is resistant to cyclophosphamide.¹³ The roles of anti-T-cell or anti-cytokine therapy in this setting are currently being tested.^{14,15} This patient is also unusual in having such severe, unremitting disease resulting in death without clinical renal involvement.




FIGURE 3

Pulmonary granuloma in Wegener's granulomatosis.

Note: peripheral Langhans type giant cell (A), a central zone of necrosis with polymorphs (B) and palisaded rim of histiocytes (C). H & E: original magnification x 20.

REFERENCES

- 1 Wegener F. Über generalisierte, septische Gefässerkrankungen. *Verhandl deutsch path Gesellsch* 1936; **29**:202-9.
- 2 Hoffman GS, Kerr GS, Leavitt RY et al. Wegener's granulomatosis: An analysis of 158 patients. *Ann Intern Med* 1992; **116**:488-98.
- 3 Carrington CB, Liebow AA. Limited forms of angiitis and granulomatosis of the Wegener's type. *Amer J Med* 1966; **41**:497-527.
- 4 Luqmani RA, Bacon PA, Beaman M et al. Classical versus non-renal Wegener's granulomatosis. *QJM* 1994; **87**:161-7.
- 5 van der Woude FJ, Rasmussen N, Lobatto S et al. Autoantibodies against neutrophils and monocytes: Tool for diagnosis and marker of disease activity in Wegener's granulomatosis. *Lancet* 1985; **1(8426)**:425-9.
- 6 Walton EW. Giant-cell granuloma of the respiratory tract. *BMJ* 1958; **2**:265-70.
- 7 Gordon M, Luqmani RA, Adu D et al. Relapses in patients with a systemic vasculitis. *QJM* 1993; **86**:779-89.
- 8 Adu D, Pall A, Luqmani RA et al. Controlled trial of pulse versus continuous prednisolone and cyclophosphamide in the treatment of systemic vasculitis. *QJM* 1997; **90**:401-9.
- 9 Guillevin L, Cordier J-F, Lhote F et al. A prospective multi center randomised trial comparing steroids and pulse cyclophosphamide versus steroids and oral cyclophosphamide in the treatment of generalised Wegener's granulomatosis. *Arthritis Rheum* 1997; **40**:2187-98.
- 10 Andrassy K, Erb A, Koderisch J et al. Wegener's granulomatosis with renal involvement: Patient survival and correlations between initial renal function, renal histology, therapy and renal outcome. *Clin Nephrol* 1991; **35**:139-47.
- 11 Geffriaud-Ricouard C, No'l LH, Chauveau D et al. Clinical Spectrum associated with antineutrophil cytoplasmic antibodies of defined antigen specificities in 98 selected patients. *Clin Nephrol* 1993; **39**:125-36.
- 12 Nachman PH, Hogan SL, Jenette JC et al. Treatment response and relapse in antineutrophil cytoplasmic antibody associated microscopic polyangiitis and glomerulonephritis. *J Am Soc Nephrol* 1996; **7**:33-9.
- 13 Luqmani RA. Is it possible to offer evidence-based treatment for systemic vasculitis? *Scand J Rheumatol* 2000; **29**:211-15.
- 14 Rasmussen N, Jayne DRW, Abramowicz D et al. European therapeutic trials in ANCA associated systemic vasculitis: disease scoring, consensus regimens and proposed clinical trials. *Clin Exp Immunol* 1995; **101(Suppl 1)**:29-34.
- 15 Stone J, Hellmann DB, Uhlfelder MI et al. Etanercept in Wegener's granulomatosis (WG). Results of an open-label trial. *Arthritis Rheum* 1999; **42(Suppl)**:S315.